

# Amniotic membrane wrapping in experimental renal trauma: A new treatment model (\*)

Ata ERDENER, Ali AVANOĞLU, İbrahim ULMAN, Mustafa ÜNLÜ,  
Saliha SOYDAN and Acun GÖKDEMİR

Department of Pediatric Surgery, Ege University Faculty of Medicine, Izmir, Turkey

## Summary

The effect of amniotic membrane wrapping on the healing of experimentally induced renal lesions were evaluated in 27 albino rats. Standart pararenal incisions were created on unilateral kidneys of 22 rats and only sham-laparotomies were made in five. Lacerated kidneys of 12 animals were wrapped with human amniotic membrane immediately after trauma and only digital hemostasis was applied to the remaining ten rats. At the 30th postoperative day, prior to sacrifice Technetium 99m-Dimercaptosuccinic acid (DMSA) scans of whole kidneys were obtained, both in plain and computerized tomographic sections, and also drug uptake of each kidney was calculated for making comparisons between the function of the contralateral kidneys. Same comparisons were made for

detecting probable functional changes between treated and nontreated groups. The wound healing in the traumatized kidneys were evaluated histopathologically. Scintigraphic defects were seen in a few of the nontreated kidneys, although there were no significant functional differences between groups. Histopathological examinations revealed that human amniotic membrane did not induce an exaggerated foreign body reaction in the healing rat tissues and a better wound healing was observed in traumatic rat kidney lesions treated with human amniotic membrane. It is concluded that, amniotic membrane wrapping may be a safe method of reconstructing tissue continuity in kidney lacerations, which provides a better wound healing.

**Key words:** Renal trauma, amniotic membrane.

## Introduction

It is generally concluded that minor renal injuries with mild lacerations and contusions are treated conservatively and severe renal injuries with deep lacerations are treated surgically by suturing the parenchymal lesions, by gluing with adhesives such as fibrinogen or by partial nephrectomy if vascular structures are impaired (1-3). Although a few percent of renal traumas require surgical intervention, there are still controversies about the best technique. Three main points have the highest priorities in the surgical treatment of renal traumas: control of the bleeding, conserving the renal function and establishing an optimal wound healing. In deep kidney lacerations a satisfactory

hemorrhage control can be obtained by partial nephrectomy or by suture repair; however, massive tissue loss or a bad wound healing will probably cause a significant decrease in renal function. In gluing the kidney lacerations with fibrin adhesives, the results will be better than above, but again an acceptable wound healing cannot be provided because of the heavily scarred tissues. In recent years, wrapping the kidney with synthetic absorbable materials such as polyglycolic acid or polyglactin mesh seems to be an available method in repairing the severe renal injuries (7,9). In our study we tested the effect of amniotic membrane wrapping on the healing of experimentally induced renal lesions.

## Materials and Methods

Twenty seven albino rats weighing approximately 200g were used in the experiment. Each of them was anesthetized with 3 % Chloral hydrate solu-

(\*) Presented at the 6th International Congress of Pediatric Surgery, Istanbul, Turkey, August 29-31, 1989  
Address: Dr. Ata Erdener, Ege University Faculty of Medicine, Department of Pediatric Surgery, 35100 Bornova, Izmir, Turkey.

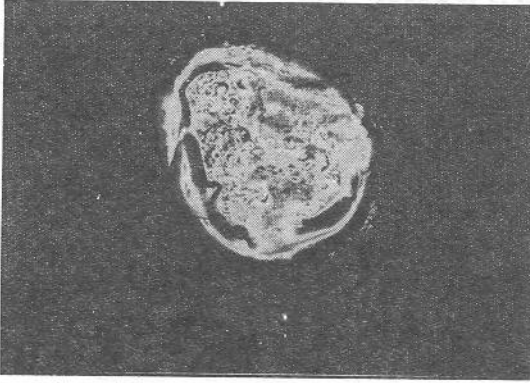


Fig. 1. Circular sheet of amniotic membrane ready for wrapping.

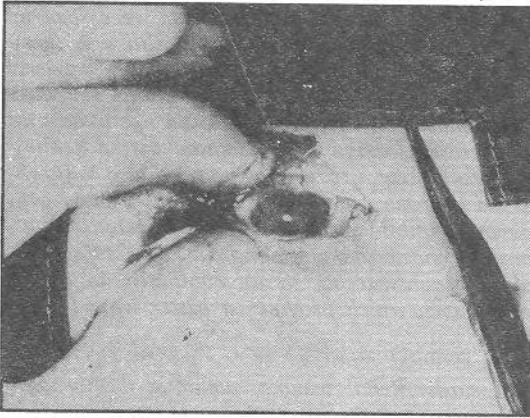


Fig. 2. Wrapping procedure: Amniotic membrane is constricted around the renal hilus.

tion by injection 1 ml/100g of body weight intraperitoneally.

In the supine position a median laparotomy was made and the left kidney of the animals was exposed. In 22 of the rats, three standart incisions involving renal cortex and extending from hilus to the lateral edge were made on the anterior surfaces of the left kidneys. Bleeding was controlled by gentle digital compression.

Human placentas were kept in sterile environment and amniotic membrane was peeled from placenta by finger dissection. The amnion was prepared according to Dino's method<sup>(4)</sup> and store in saline solution with amikacine sulphate 500 mg/l in a glass bottle for 24 hours at 4°C. Immediately after trauma, a circular sheet of amnion in 3 cm diameter was created (Fig 1) and the injured left kidneys of 12 rats were wrapped with amnion (Fig 2). The free edges of the membrane was constricted with absorbable purse string suture around the renal hilus (treated group). In ten rats no surgical treatment was applied after digital hemorrhage control (nontreated group). Sham-laparotomies were performed in five of the animals to obtain normal left kidney scintigrams.

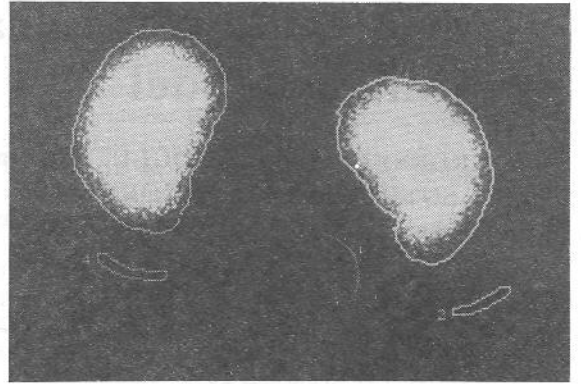


Fig. 3. Scintigraphic defect at the medial border of the traumatized left kidney in the nontreated group.

At the 30th postoperative day, under Chloral hydrate anesthesia, plain and computerized renal scans were obtained with a Toshiba GCA 601 gamma camera, three hours after the intravenous injection of 200 mCi/kg of Technetium 99m/DMSA (Amerscan, Amersham, UK), a cortical scanning agent which specifically localizes in the proximal tubular cells<sup>(8)</sup>. Digital anterior, posterior and computerized tomographic images were acquired on the computer and the total and average counts of "region of interests" and back ground activities of each kidney were calculated.

After sacrifice, routine aerobic cultures of swabs of the renal surfaces of the affected kidneys were obtained and both kidneys were removed and examined grossly and histologically using standart techniques.

Student's t-test was used for significant difference between the mean values of DMSA uptakes of groups. Regression analysis was made between contralateral kidneys in each group.

## Results

Full hemostatis was obtained in all of the groups. None of the animals died in the experiment. Cultures of renal surfaces in all rats were sterile.

All of the traumatized kidneys seemed normal in computerized tomographic scans, but in plain anterior images, two animals in the nontreated group showed defects characterized by focal areas of decreased uptake of DMSA and one animal revealed diffuse decreased uptake of DMSA in the traumatized left kidney (Fig. 3). In amniotic membrane group all of the scintigraphic views were normal. In the macroscopic examination, all of the traumatized kidneys of the nontreated group were irregular in shape. The healed lacerations were deep and wide and most of them contained hematoma. Four

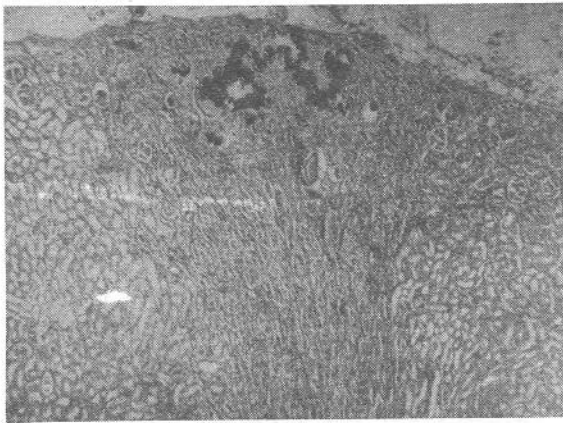


Fig. 4. Secondary wound healing in a nontreated kidney (H.E. X10).

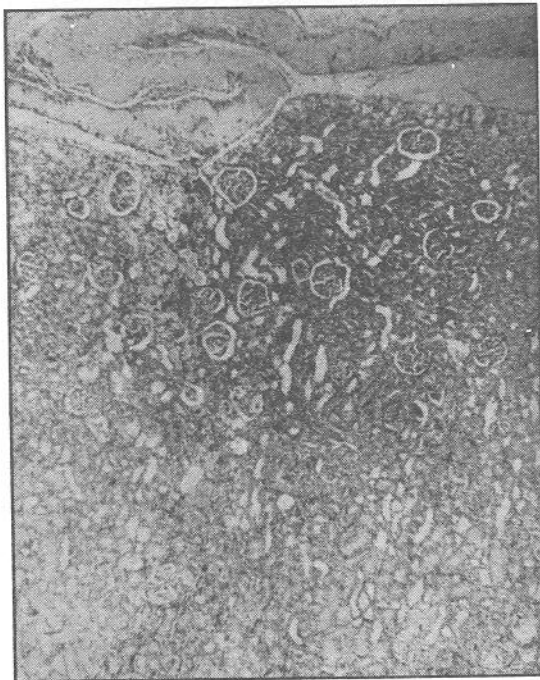


Fig. 5. Primary wound healing of the incision under the amniotic membrane (H.E. X10).

of the kidneys in the treated group had adhesions with the liver or spleen, but the kidneys could easily be released from surrounding organs. The amniotic membrane attached to the surface of the kidney could be peeled easily. There were no signs of perirenal fibrosis or hematoma.

In the histopathologic examination there were organized hematomas in at least one incision of the kidney of the non-treated group. Connective tissue proliferation, wide calcification areas and large number of macrophages loaded with hemosiderin pigment were the characteristic scenes of the wounds. Because of the contraction and the organization of the hematoma, there were wide defects

Table I. The comparison of the Tc99m-DMSA uptake ratios (\*)

	Tc 99m-DMSA uptake (Average counts) Affected kidney/ Normal kidney
Treated group (n=12) r=0.912	0.9763 0.8594 0.9076 0.9728 0.7243 1.0328 1.0954 1.0533 0.9373 0.8945 0.8371 1.0445
	(mean: 0.9438±0.10)
Non-treated group (n=10) r=0.974	0.9257 0.9374 0.9796 0.8429 1.0060 0.8031 0.8497 1.0590 0.9612 1.0122
	(mean: 0.9372±0.08)
Sham laparotomy group (n=5) r=0.986	0.9302 0.8745 1.0919 1.0027 0.9244
	(mean: 0.9647±0.08)

(\*) The comparison of the Tc99m-DMSA uptake ratios (affected kidney/normal kidney) of three groups revealed no significant difference between them ( $p>0.05$ ) and the uptake scores of the affected and normal kidneys correlated well in each of the groups ( $r$ : regression co-efficient).

extending to the medulla (Fig. 4). In the treated group the renal capsule was thin and regular. The amniotic membrane was adhered to the surface of the lacerated kidney but the foreign body reaction was nonsignificant with only a few mononuclear cells near the incision (Fig 5). The scars were thin and healed well. Those were the findings of primary healing of the parenchyma, contrary to the findings of nontreated group, in which secondary wound healing was observed.

Statistically, there were no significant difference between mean DMSA uptake ratios of each group. DMSA uptake also showed a perfect parallelism between contralateral kidneys in each group, according to regression analysis (Table 1).

## Discussion

There have been limited experimental experiences in the surgical treatment of severe renal injuries. To control the bleeding, suturing or gluing the parenchymal lesions or heminephrectomy would be very effective, but an undesirable bad wound healing would cause a possible decrease in renal function especially after heminephrectomy.

Recently, many years after the first idea of treating a damaged kidney by external splinting, promising results were reported either experimentally or clinically about wrapping the lacerated kidney with absorbable materials such as polyglycolic acid mesh (7,9). Keeping the idea of external splinting in mind, we have lighted up to use amniotic membrane as an alternative to polyglycolic acid and other materials used for wrapping the kidney. Amniotic membrane was investigated by a large number of authors and proved to be an excellent bioprosthesis for various parts of the organism (5,6,10,11).

There were no significant differences of renal function between the treated and nontreated groups; so, it can be asked if surgical treatment is necessary in the management of the "moderately" severe injured kidneys or not. Although we are not able to show a functional decrease in the nontreated kidneys, we believe that with a more sensitive technique, a functional decrease can be identified because of the heavily scarred tissues and giant hematoma formations in the non-treated kidneys. This must be remembered in the management of a clinical case.

We preferred to apply human amniotic membrane in experimentally induced renal lesions and suggested that it can be used safely for the following advantages and superiorities: (1) The technique is easy to perform; (2) it attaches to the surface of the lacerated kidney and provides a primary wound healing preventing the formation of hematoma; (3) it is transparent (So, a good hemorrhage control

can confidently be made); (4) it does not induce an exaggerated foreign body reaction or inflammation; (5) probably a "Page-effect" will not be seen because there is no evidence of perirenal fibrosis renal cortical ischemia, foci of chronic inflammation or focal scars of the glomeruli; (6) it is cheaper than its equivalents.

**Acknowledgements:** The authors wish to thank Prof. Dr. Günaydın Erbençi from the Department of Nuclear Medicine of Hacettepe University, Ankara, for her valuable contributions in nuclear scanning of rat kidneys.

## References

1. Brands W, Haselberger J, Mennicken C, Hoerst M: Treatment of ruptured kidney by gluing with highly concentrated human fibrinogen. *J Pediatr Surg* 18:611-613, 1983.
2. Cass AS: Renal trauma in the multiple injured patient. *J Urol* 114:495-497, 1975.
3. Cass AS, Luxenberg M: Conservative or immediate surgical management of blunt renal injuries. *J Urol* 130:11,16, 1983.
4. Dino BR, Eufemuo GG, DeVilla MS: Human amnion: The establishment of an amnion bank and its practical applications in surgery. *J Philippine Med Assoc* 42:357, 1966.
5. Fishman IJ, Flores FN, Scott FB: Use of placental membranes for bladder reconstruction. *J urol* 138:1291, 1987
6. Gray KJ, Shenaq SM- Engelman UH, Fishman IJ, Jeraj K, Spira M: Use of human amnion for microvascular interpositional grafts. *Plast Reconstr Surg* 79:778, 1987.
7. Lau JL, Fowler JE, Stobnicki M, Ray V, Forrest R: Polyglycolic acid mesh in experimental renal trauma. *J Urol* 136:715, 1986
8. Moretti JH, Rapin JR, LePoncin M, Lageron A, Saccavini JC, Bardy A: Dimercaptosuccinic acid complexes: their structure, biological behaviour and renal localization. Joekes AM, Constable AR, Brown NJG, Tauxe WN (E) "Radionuclides in Nephrology", London, Academic Press, 1982, p:25
9. Schonenberger A, Mettler D, Roesler H, Zimmerman A, Bilweis J, Schilt W, Zingg EJ: Surgical repair of the kidney after blunt lesions of intermediate degree using a Vicryl mesh: an experimental study. *J Urol* 134:804, 1985.
10. Scudamore CH, Becker CD- Fache JS, Bianco R, Shackleton CR, Burhenne HJ, Owen DA, Schechter MT, Seccombe D: Human amnion as a bioprosthesis for bile duct reconstruction in the pig. *Am J Surg* 155:635, 1988.
11. Trelford JD, Trelford-Sauder M: The amnion in surgery, past and present. *Am J Obstet Gynecol* 134:833, 1979.