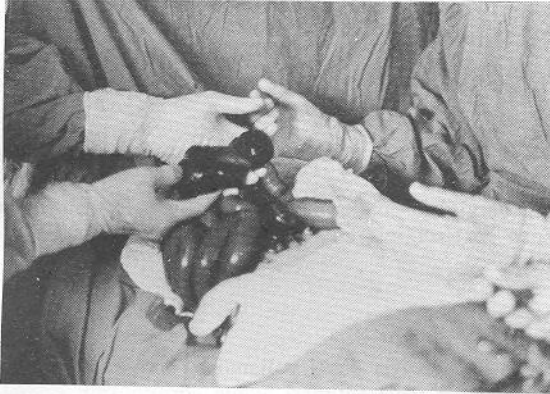


Mesenteric cyst: A rare cause of intestinal obstruction

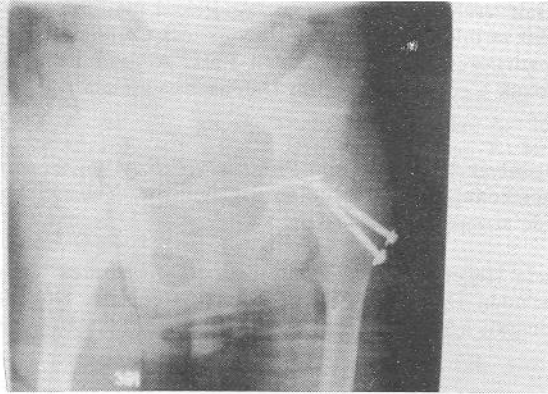


Faik Çelik

Department of General Surgery, SSK Hospital, Rize, Turkey

Mesenteric cyst is a rare cause of intestinal obstruction in children. A five year old boy with complete ileal obstruction due to a dumbbell shaped mesenteric cyst who was treated by resection of the ileal segment with cystic mass and primary anastomosis of the intestine is presented.

Iatrogenic foreign bodies in childhood



Bozkurt TAYLAN, Kenan HASPOLAT, Hüseyin TEKYİĞİT

From the Department of Pediatrics, Department of Orthopedics and Traumatology, Department of General Surgery, SSK Ereğli Hospital, Konya, Turkey

A 12 year old boy was admitted to the hospital because of long lasting abdominal pain. Plain X-ray examination of the abdomen revealed the existence of a metallic foreign body in the pelvic region. It was learnt that he had an operation for epiphysiolysis of his left femur and a Steinmann wire had been inserted as a surgical procedure. Laparotomy proved that the urinary bladder was penetrated by the Steinmann wire. After pulling out the wire, child was discharged from the hospital without any complications.

Editors comment:

We believe that interesting case reports should be published in Pediatric Surgery. Brief English summary and informative picture of the case suffice to inform the reader. This kind of presentation also helps in sparing the limited number of pages of the journal for other writers.

C. Büyükkunal - O.F. Şenyüz