




How to approach cases of anal atresia with rectoscolotal fistula: Low or intermediate?

Aziz Serhat Baykara 

Anal atresia or anorectal malformation (ARM) refers to a spectrum of anorectal abnormalities ranging from a membranous separation to complete absence of the anus. The incidence of anal atresia is 1 in 5,000 live births.^[1] The majority of male patients (80-90%) have evidence of a fistula.^[2,3] The most common defect in females is rectovestibular fistula, whereas the most common defect in males is rectourethral fistula.^[2] Anal atresia without fistula occurs in 5% of patients.^[4] A fistula exiting at the scrotal raphe, described in our case, is very rare. Herein, we present the case of a male neonate with anal atresia and a fistula exiting at the scrotal raphe.

CASE REPORT

A 2,750-g male infant was born following uncomplicated gestation and normal delivery at term. Family history was unremarkable. The infant was referred to our facility four days after birth in good general status and with a slightly distended abdomen. On closer inspection, the anus was observed to be absent, with a normally placed anal dimple and a well-formed midline bottom cleft (Figure 1). The external male genitalia appeared normal. A small midline opening was uncovered in the mid-scrotum by passing a fine infant feeding tube. The tube

Abstract

Anorectal malformation is a congenital condition where the anus, which opens into the rectum, is missing, malformed, or has a blockage that does not allow feces to pass from the body. These malformations often present with an enteroperineal or enterourinary tract fistula in male children. Anorectal atresia with rectoscolotal fistula is rare. Herein, we present the case of a neonate with imperforate anus and a fistula on the scrotal raphe. A fistula in front of the scrotum, described in our case, is very rare and not incorporated in the current classification and treatment algorithms. Scarce reports on misjudgment concerning the position of the blind rectal pouch in similar cases, led us to perform a colostomy instead of a one-stage correction. We believe that in cases with a rare fistula presentation, the position of the rectal pouch is not predictable and the surgeon should proceed with caution.

Keywords: Anal atresia, anorectal malformation, rectoscolotal fistula.

appeared to pass upwards and obliquely, indicating that this was not a low type of ARM.

A contrast study performed through the fistula confirmed the diagnosis of an intermediate type of ARM with a long rectoscolotal fistula (Figure 2). The infant's urine did not contain meconium. Routine laboratory findings were normal. A thorough ultrasound examination did not reveal any associated anomalies. A diverting sigmoid colostomy was created a couple of hours later. The postoperative course was uncomplicated. Posterior sagittal anorectoplasty (PSARP) was performed when the patient weighed 10 kg. A distal loopogram was performed before PSARP. Intraoperative findings included a scrotal dimple with a rectoscolotal fistula 2 mm in diameter that could be cannulated with a microprobe. The rectal stump was detected at the level of the bulbous urethra in the perineum. Postoperative recovery was uneventful, and stoma closure was performed three months later. The patient is currently 10 months old, and the anal dilatation program is being continued.

Received: January 02, 2024

Accepted: February 07, 2024

Published online: March 27, 2024

Correspondence: Aziz Serhat Baykara, MD.

E-mail: asbaykara@hotmail.com

Department of Pediatric Surgery, University of Health Sciences, Eskişehir City Hospital, Eskişehir, Türkiye.

Citation:

Baykara AS. How to approach cases of anal atresia with rectoscolotal fistula: Low or intermediate? Turk J Pediatr Surg 2024;38(1):27-30. doi: 10.62114/JTAPS.2024.14.

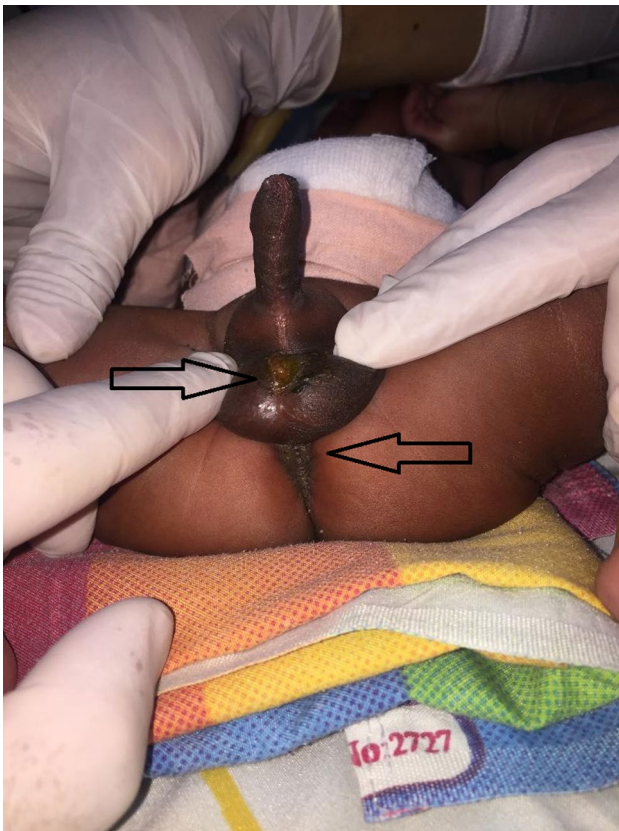


Figure 1. Anorectal atresia with fistula in scrotal raphe.

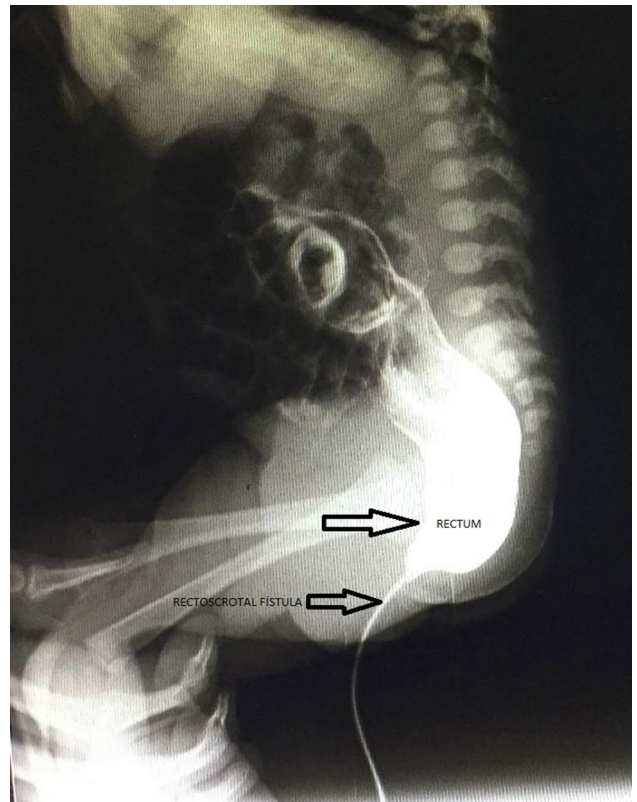


Figure 2. Contrast-enhanced fistulogram study showing the rectosigmoid fistula.

DISCUSSION

Anorectal malformations occur during embryonal life when there is a pause in the development of the anal, genital, and urinary components.^[1,5] The origin of these malformations remains unclear and is likely attributable to many factors. In male patients, rapid and diffuse enlargement of the perineum usually prevents the development of fistulas anterior to the scrotum. This condition defines anomalies that can occur with enteroperineal or enterourinary tract fistula in males.^[6]

Anorectal malformation type is essential for classification and guides the treatment plan. The initial classification of ARM was based on the position of the rectum compared to the levator ani or pelvic floor. The Wingspread classification was made according to the level of arrest of the rectal descent and the sex of the patient.^[7] However, after the introduction of the PSARP approach by Peña,^[8]

there have been significant changes in the surgical approach of these patients. In addition, advances in imaging techniques with a deeper understanding of the embryology, anatomy, and pathophysiology of ARM cases have aided in the diagnosis and classification of this condition. A new classification system based on the presence and location of the fistula, grouped by sex and resulting from experience with PSARP, was proposed in 1995.^[9] To standardize the methodology for evaluating patient outcomes, the Krickbeck group developed a classification that included criteria from both Sacks et al.^[10] It consisted of three components: a diagnostic category, a surgical procedure category, and a category documenting functional outcome criteria.

Anorectal malformations are referred to as high, medium, or low according to the position of the blind rectal pouch to the pelvic floor muscle complex.^[11] A fistula typically connects the atretic intestine to the perineal skin, scrotum, or urogenital tract. Advances in imaging modalities and radiological techniques

have also made it possible to precisely define the location of the fistula. Perineal or scrotal fistulas associated with high and moderate ARM do not appear in the standard classification system. Our case represents a rare presentation of an intermediate-type ARM associated with scrotal fistula.

Anorectal malformation classification is crucial for treatment planning. In low-type cases, an anoperineal fistula is usually found between the scrotum and anal dimple, and this can be treated in a single session with limited PSARP.^[11] However, in medium- or high-type ARM, diverting colostomy is usually performed first,^[9] and then a definitive operation is performed. Therefore, it is essential to identify the abnormality before intervention. The presented case consisted of a medium-type ARM in which the scrotal fistula was opened to the level of the levator muscle. This case exemplifies a rare variant of ARM in which the rectoscrotal fistula may be associated with intermediate- and high-type anomalies. A rare-variant ARM with rectoscrotal fistula may be associated with intermediate- or high-type anomalies, contrary to the classical classification. The management of these cases must be carefully planned due to the possible need for urethral repair during anorectoplasty.

Few cases of this rare variant of ARM have been reported in the literature. In a series of nine cases presented by Fitzgerald et al.,^[12] it was reported that the tract opened into the rectum at the translevator level in ARMs with fistula opening into the scrotum. Furthermore, Jadhav and Rijwani^[13] reported that the fistula opened into the rectum at the translevator level in a baby with a rectoscrotal fistula. With these case reports, it was recommended to detect the fistula tract by various methods in ARMs with fistula detected in the scrotal region and to open a colostomy as the first surgical procedure before definitive surgery when a recto-scrotal fistula is detected. The main goal in the treatment of ARM is to provide improvement in quality of life and complete fecal and urinary continence.^[8,11] Definitive treatment at the appropriate time and under the right conditions positively affects the quality of life in the future.^[8] Long-term follow-up is needed to evaluate bowel continence for our patient who had PSARP.

In conclusion, although the classifications for ARMs can guide surgical approaches to these patients, atypical presentations may not follow

conventional treatment approaches. Rare-variant ARMs with rectoscrotal fistula may be associated with intermediate- or high-type anomalies, unlike classical rectoperineal fistula. In this case, a diverting colostomy should be opened first, and then a definitive operation should be planned.

Patient Consent for Publication: A written informed consent was obtained from the parent of the patient.

Data Sharing Statement: The data that support the findings of this study are available from the corresponding author upon reasonable request.

Conflict of Interest: The author declared no conflicts of interest with respect to the authorship and/or publication of this article.

Funding: The author received no financial support for the research and/or authorship of this article.

REFERENCES

1. Smith CA, Avansino J. Anorectal malformations. 2023 Aug 8. In: StatPearls [Internet]. Treasure Island (FL): StatPearls Publishing; 2024.
2. Levitt MA, Peña A. Anorectal malformations. *Orphanet J Rare Dis* 2007;2:33. doi: 10.1186/1750-1172-2-33.
3. Nam SH, Kim DY, Kim SC. Can we expect a favorable outcome after surgical treatment for an anorectal malformation? *J Pediatr Surg* 2016;51:421-4. doi: 10.1016/j.jpedsurg.2015.08.048.
4. Gangopadhyay AN, Pandey V. Anorectal malformations. *J Indian Assoc Pediatr Surg* 2015;20:10-5. doi: 10.4103/0971-9261.145438.
5. Bischoff A, Levitt MA, Lim FY, Guimarães C, Peña A. Prenatal diagnosis of cloacal malformations. *Pediatr Surg Int* 2010;26:1071-5. doi: 10.1007/s00383-010-2685-3.
6. Jun LH, Jacobsen A, Rai R. Case report: A case series of rare high-type anorectal malformations with perineal fistula: Beware of urethral involvement. *Front Surg* 2021;8:693587. doi: 10.3389/fsurg.2021.693587.
7. Nah SA, Ong CC, Lakshmi NK, Yap TL, Jacobsen AS, Low Y. Anomalies associated with anorectal malformations according to the Krickenbeck anatomic classification. *J Pediatr Surg* 2012;47:2273-8. doi: 10.1016/j.jpedsurg.2012.09.017.
8. Peña A. Anorectal malformations. *Semin Pediatr Surg* 1995;4:35-47.
9. Qazi SH, Faruque AV, Mateen Khan MA, Saleem U. Functional outcome of anorectal malformations and associated anomalies in era of Krickenbeck classification. *J Coll Physicians Surg Pak* 2016;26:204-7.
10. Sacks D, Baxter B, Campbell BCV, Carpenter JS, Cognard C, Dippel D, et al. Multisociety Consensus Quality Improvement Revised Consensus Statement for Endovascular Therapy of Acute Ischemic Stroke. *Int J Stroke* 2018;13:612-632. doi: 10.1177/1747493018778713.
11. Holschneider A, Hutson J, Peña A, Beket E, Chatterjee S, Coran A, et al. Preliminary report on the International Conference for the Development of Standards for the Treatment of Anorectal Malformations. *J Pediatr Surg* 2005;40:1521-6. doi: 10.1016/j.jpedsurg.2005.08.002.

12. Fitzgerald RJ, Watters K, Bissett WH, Bjordal R, Monclair T. Translevator anal anomalies with cutaneous fistulae passing deep to the scrotum. *J Pediatr Surg* 2002;37:1326-9. doi: 10.1053/jpsu.2002.35001.
13. Jadhav BB, Rijwani A. Anorectal atresia with rectoscrotal fistula: A rare anorectal malformation. *J Neonatal Surg [Internet]* 2018;7:13.