

# A two-month-old infant with achalasia: A case report

Gonca Gerçel<sup>1</sup>, Sefa Sağ<sup>2</sup>, Furkan Adem Canbaz<sup>3</sup>, Yağmur Sönmez<sup>4</sup>, Esmâ Karadeniz Güngörmez<sup>5</sup>

Achalasia is a primary functional motor disorder of the lower esophageal sphincter (LES), characterized by abnormal esophagus motility and failure to relax the LES.<sup>[1]</sup> It usually manifests in the fourth and fifth decades of life. It is rare in childhood, with an estimated annual incidence of only 0.02 to 0.11 cases per 100,000 children, and extremely rare under the age of one year.<sup>[2,3]</sup>

In children, the symptoms of the disease vary according to age. However, the most common symptoms are dysphagia, regurgitation of undigested food, vomiting, cough, chest pain, heartburn, recurrent pneumonia, and poor weight gain or weight loss.<sup>[4,5]</sup> These symptoms can easily be misdiagnosed as gastroesophageal reflux disease and may lead to delays in treatment.

The main principle in treating achalasia is to eliminate the functional obstruction at the level of the gastroesophageal junction.<sup>[6]</sup> The traditional management of children with achalasia includes medication, endoscopy, and Heller surgery.

Herein, a child with achalasia treated with Heller myotomy with a Dor fundoplication is presented. To our knowledge, this patient is one of the youngest

## Abstract

Achalasia is a primary functional motor disorder of the lower esophageal sphincter, characterized by abnormal esophagus motility and failure to relax the lower esophageal sphincter. Herein, we present a case of a two-month-old female infant who was operated on with a diagnosis of achalasia. The baby was born at 39 weeks with cesarean section, with a birth weight of 3180 g, and referred to the pediatric surgery clinic with the suspicion of tracheoesophageal fistula. Physical examination was unremarkable except for malnutrition. The patient had been receiving gastroesophageal reflux treatment since the neonatal period. An upper gastrointestinal series revealed dilatation in the lower two-thirds of the esophagus and a typical bird's beak appearance at the esophagogastric junction. Heller myotomy with Dor fundoplication was performed. The postoperative follow-up was uneventful. The patient presented is one of the youngest children operated with achalasia in the literature. Achalasia should be kept in mind in the presence of frequent pulmonary infections, weight loss, and oronasal regurgitation unresponsive to antireflux therapy.

**Keywords:** Achalasia, case report, Heller, infant, surgery.

reported children operated for achalasia in the literature.

## CASE REPORT

A two-month-old female infant presented with complaints of dysphagia, oronasal regurgitation, failure to gain weight, and frequent lung infections since birth. The girl regurgitated every feed effortlessly, even upright, within minutes of ingesting food. The baby was born at 39 weeks with cesarean section, having a birth weight of 3180 g, and had a history of hospitalization in the intensive care unit with a diagnosis of pneumonia in the neonatal period and three hospitalizations due to pneumonia in total. There was no response to antireflux medication. The patient had no family history of the same illness.

On physical examination, the baby was malnourished, with a weight of 3400 g


Received: January 17, 2024  
Accepted: March 01, 2024  
Published online: March 27, 2024

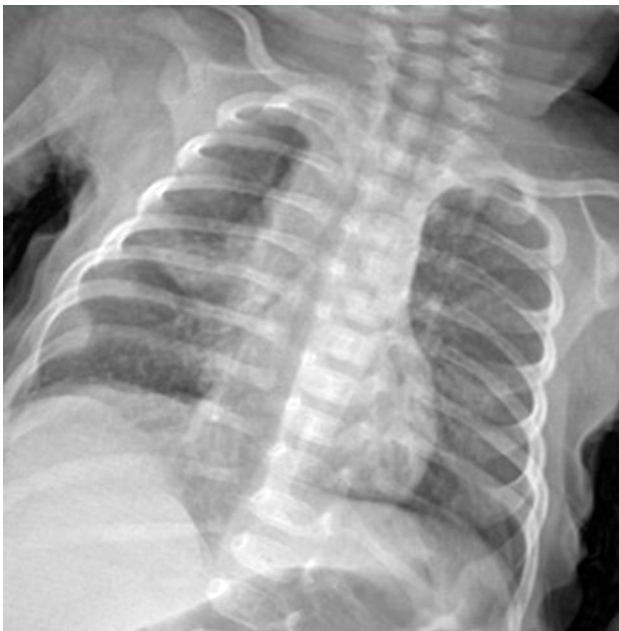Correspondence: Gonca Gerçel, MD.  
E-mail: goncagercel@gmail.com

Department of Pediatric Surgery, Sancaktepe Şehit Prof. Dr. İlhan Varank Training and Research Hospital, İstanbul, Türkiye

## Citation:

Gerçel G, Sağ S, Canbaz FA, Sönmez Y, Karadeniz Güngörmez E. A two-month-old infant with achalasia: A case report. Turk J Pediatr Surg 2024;38(1):35-38. doi: 10.62114/JTAPS.2024.20.

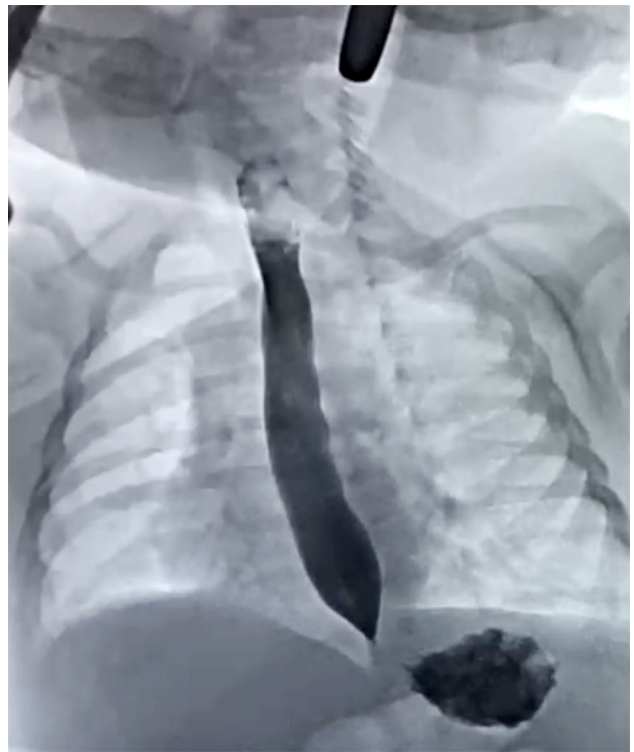 This is an open access article licensed under the Creative Commons Attribution-NonCommercial 4.0 International License (CC BY-NC 4.0). <https://creativecommons.org/licenses/by-nc/4.0/>



**Figure 1.** Posteroanterior radiograph revealing right patchy opacities suggesting bronchopneumonia.

(<3<sup>rd</sup> percentile) and height of 53 cm (between the third and 10<sup>th</sup> percentile). On examination of the respiratory system, bilateral crepitations were detected. Examination of other systems was unremarkable. Routine laboratory investigations were within normal limits. The chest X-ray demonstrated right patchy opacities, suggesting bronchopneumonia (Figure 1). The patient was diagnosed with bronchopneumonia and treated with intravenous antibiotics, salbutamol, and budesonide.

An upper gastrointestinal series was planned for the patient due to the persistence of regurgitation on feeding, which revealed dilatation in the lower two-thirds of the esophagus and a typical bird's beak appearance at the esophagogastric junction (Figure 2). Other causes of obstruction, such as reflux esophagitis, stricture, and diverticulum, were excluded by esophagoscopy. Esophageal manometry could not be performed due to technical inadequacy. Surgery was decided for the patient. Heller myotomy through an open abdominal approach with the antireflux procedure (Dor fundoplication) was performed. The patient was discharged on the postoperative Day 11 with full oral nutrition. The eight-month postoperative follow-up of the patient was uneventful. Weight gain was in the normal percentile range.



**Figure 2.** Contrast esophagogram showing lower esophageal dilation with a bird's beak appearance at the esophagogastric junction.

## DISCUSSION

Achalasia is a motor disorder of the esophagus characterized by the inability of the LES to provide a coordinated relaxation response to esophageal peristalsis stimulated by deglutition.<sup>[1,2]</sup> Dysmotility of the LES during swallowing and abnormal esophagus peristalsis occur due to neuromuscular disorders such as ganglion cell degeneration. This may be due to an abnormality in the Auerbach's plexus, responsible for smooth muscle relaxation. This leads to dilatation of the esophagus and stasis of swallowed food, causing problems related to regurgitation and aspiration.<sup>[7]</sup>

Achalasia symptoms vary according to age. Symptoms in older children are similar to those in adults, with vomiting, regurgitation of undigested food, retrosternal burning, and chest pain. In infants, it manifests with symptoms such as regurgitation, choking, frequent lung infections, weight loss, and growth retardation.<sup>[8]</sup> Due to the similarity of symptoms with gastroesophageal reflux, these patients may be misdiagnosed, and delays in diagnosis and treatment may occur, as in the

presented patient. In patients who do not respond to antireflux treatment, it is necessary to be alert for other underlying diseases such as achalasia.

Achalasia is a rare disorder with an incidence of four to six cases per million population per year, and only 5% of cases are aged less than 15 years, with only 6% of reported cases in childhood being diagnosed in infancy.<sup>[9]</sup> Therefore, the optimal management of achalasia in children remains to be determined. To our knowledge, this patient is one of the youngest reported children operated for achalasia in the literature.

In most infants, clinical findings and contrast-enhanced esophagogram will reliably provide the diagnosis. The contrast-enhanced esophagogram may show a dilated esophagus with narrowing of the distal esophagus and esophagogastric junction, also described as a bird-beak sign.<sup>[10]</sup> Endoscopy is also diagnostic in supporting the diagnosis of achalasia. The smooth narrowing of the distal esophagus is differentiated from peptic stenosis related to gastroesophageal reflux at endoscopy since the distal esophagus can be easily passed and the mucosa is normal. However, endoscopic evaluation is necessary to rule out other causes of esophageal obstruction (e.g., congenital membrane, acquired stricture, and eosinophilic esophagitis). The esophageal manometry reveals high LES resting pressure with incomplete LES relaxation with swallows.<sup>[10,11]</sup> Although esophageal manometry is the key diagnostic test, it is less commonly used, particularly in small children, due to technical difficulties. In the present patient, the diagnosis was confirmed by contrast esophagogram and endoscopy. Esophageal manometry could not be performed due to technical inadequacy.

The main principle in treating achalasia is to eliminate the functional obstruction at the level of the gastroesophageal junction. Traditionally, medication, botulinum toxin injection, pneumatic balloon dilatation, and surgical myotomy are treatment methods for achalasia.<sup>[12,13]</sup> Medical treatment includes nitrates and calcium channel blockers and is limited for use in children. There are reports in the literature that pneumatic dilatation and botulinum toxin injection improves symptoms, but these methods provide short-term relief and may require repeated procedures.<sup>[14,15]</sup> Currently, surgical myotomy is the most effective method for childhood achalasia in many centers.<sup>[14]</sup> Myotomy

can be performed conventionally, laparoscopically, and endoscopically (peroral endoscopic myotomy). Laparoscopic and endoscopic myotomy in infants can be technically challenging. In the present case, we preferred conventional Heller myotomy due to the low weight and small age of the patient.

In conclusion, the patient presented is one of the youngest children in the literature who underwent surgery with the diagnosis of achalasia. The rarity of achalasia in the childhood age group may cause delays in diagnosis. In frequent lung infections, weight loss, and oronasal regurgitation unresponsive to antireflux treatment, achalasia should be considered. Heller myotomy can be safely performed in the early infant period.

**Patient Consent for Publication:** A written informed consent was obtained from the parent of the patient.

**Data Sharing Statement:** The data that support the findings of this study are available from the corresponding author upon reasonable request.

**Author Contributions:** Study idea/concept: G.G., S.S.; Design and writing the article, references: G.G.; Data collection and/or processing/materials: F.A.C., Y.S., E.K.G.; Literature review: G.G.; Critical review: G.G., F.A.C.; Control/ supervision: S.S.

**Conflict of Interest:** The authors declared no conflicts of interest with respect to the authorship and/or publication of this article.

**Funding:** The authors received no financial support for the research and/or authorship of this article.

## REFERENCES

1. Tovar JA. Disorders of esophageal function. In: Coran AG, Adzick NS, Krummel TM, editors. Pediatric surgery. 7th ed. Philadelphia: Elsevier Saunders; 2012. p. 936-946.
2. Franklin AL, Petrosyan M, Kane TD. Childhood achalasia: A comprehensive review of disease, diagnosis and therapeutic management. *World J Gastrointest Endosc* 2014;6:105-11. doi: 10.4253/wjge.v6.i4.105.
3. Chatterjee S, Gajbhiye V, De A, Nath S, Ghosh D, Das SK. Achalasia cardia in infants: Report of two cases. *J IMA* 2013;44:44-1-9260. doi: 10.5915/44-1-9260.
4. Sato H, Takahashi K, Mizuno KI, Hashimoto S, Yokoyama J, Hasegawa G, et al. Esophageal motility disorders: New perspectives from high-resolution manometry and histopathology. *J Gastroenterol* 2018;53:484-93. doi: 10.1007/s00535-017-1413-3.
5. Chen WF, Li QL, Zhou PH, Yao LQ, Xu MD, Zhang YQ, et al. Long-term outcomes of peroral endoscopic myotomy for achalasia in pediatric patients: A prospective, single-center study. *Gastrointest Endosc* 2015;81:91-100. doi: 10.1016/j.gie.2014.06.035.
6. Singh S, Wakhlu A, Pandey A, Kureel SN, Rawat J. Retrospective analysis of paediatric achalasia in India: Single centre experience.

- Afr J Paediatr Surg 2012;9:117-21. doi: 10.4103/0189-6725.99396.
7. Jolley SG, Baron HI. Disorders of esophageal function. In: O'Neill JA, editor. Pediatric surgery. 5th ed. Boston: Mosby; 2000. p.997-1007.
8. Karnak I, Senocak ME, Tanyel FC, Büyükpamukçu N. Achalasia in childhood: Surgical treatment and outcome. Eur J Pediatr Surg 2001;11:223-9. doi: 10.1055/s-2001-17154.
9. Myers NA, Jolley SG, Taylor R. Achalasia of the cardia in children: A worldwide survey. J Pediatr Surg 1994;29:1375-9. doi: 10.1016/0022-3468(94)90119-8.
10. Khashab MA, Vela MF, Thosani N, Agrawal D, Buxbaum JL, Abbas Fehmi SM, et al. ASGE guideline on the management of achalasia. Gastrointest Endosc 2020;91:213-27.e6. doi: 10.1016/j.gie.2019.04.231.
11. Miller J, Khlevner J, Rodriguez L. Upper gastrointestinal functional and motility disorders in children. Pediatr Clin North Am 2021;68:1237-53. doi: 10.1016/j.pcl.2021.07.009.
12. Idrissa S, Oumarou A, Mahmoudi A, Elmadi A, Khattala K, Bouabdallah Y. Diagnosis and surgical management of children with oesophageal achalasia: A 10-year single-centre experience in Morocco. Afr J Paediatr Surg 2021;18:155-9. doi: 10.4103/ajps.AJPS\_46\_20.
13. Nicolas A, Aumar M, Tran LC, Tired A, Duclaux-Loras R, Bridoux-Henno L, et al. Comparison of endoscopic dilatation and heller's myotomy for treating esophageal achalasia in children: A multicenter study. J Pediatr 2022;251:134-9.e2. doi: 10.1016/j.jpeds.2022.07.010.
14. Lee CW, Kays DW, Chen MK, Islam S. Outcomes of treatment of childhood achalasia. J Pediatr Surg 2010;45:1173-7. doi: 10.1016/j.jpedsurg.2010.02.086.
15. Askegard-Giesmann JR, Grams JM, Hanna AM, Iqbal CW, Teh S, Moir CR. Minimally invasive Heller's myotomy in children: Safe and effective. J Pediatr Surg 2009;44:909-11. doi: 10.1016/j.jpedsurg.2009.01.022.