

# Double esophageal duplication cysts: A rare case report in Nicaragua

María Fernanda Marenco Gutiérrez 

Gastrointestinal (GI) tract duplication, or GI duplication cyst, is a rare congenital malformation of the GI tract. The etiology of GI tract duplication is not fully understood; however, an initial developmental abnormality during the gastrulation stage is thought to be the most likely cause, and the esophageal duplication cysts are rare congenital cystic masses resulting from an error in foregut budding in the developing embryo, with a reported incidence of one in 22,000 newborns<sup>[1-3]</sup> Herein, we presented an extremely rare case of an esophageal duplication cyst that occurred in Nicaragua.

## CASE REPORT

A female neonate born at 37 weeks of gestation weighing 3,735 g had APGAR scores of 8 and 9 at 1 and 5 min, respectively. Despite a prenatal diagnosis of CDH, the patient was stable and free of respiratory distress at birth. Computed tomography confirmed the integrity of the diaphragm and revealed a large septated cyst measuring 132×59×41 mm with a volume of 120 mL, located extrapleurally in the right paravertebral area. This cyst was compressing the right atrium and trachea. An additional cyst was identified in the posterior mediastinum, situated between the esophagus and spinal column. The infant underwent surgical resection of the larger

## Abstract

Esophageal duplication cyst is a rare congenital anomaly arising from the posterior primitive foregut, typically located in the thoracic esophagus. Herein, we reported the case of a female newborn who was prenatally diagnosed with congenital diaphragmatic hernia. A subsequent computed tomography scan revealed an intact diaphragm and a large septated cyst measuring 132×59×41 mm with a volume of 120 mL, situated extrapleurally near the right paravertebral area. Surgical intervention involved a right thoracotomy under general anesthesia to remove the larger cyst, which was connected to the esophagus via an obliterated fistula. There was no communication between this cyst and the trachea. Histological examination of the removed cyst revealed four layers of tissue, consistent with esophageal tissue: mucosa, submucosa, muscularis propria, and either serosa or adventitia. A six-month follow-up ultrasound confirmed no residual disease or recurrence. This case marks only the fourth such instance reported globally.

**Keywords:** Children, congenital diaphragmatic hernia, esophageal duplication cyst.

cyst through a right thoracotomy under general anesthesia. The cyst was found to be connected to the esophagus via an obliterated fistula, with no evidence of communication with the trachea (Figure 1).

The smaller esophageal cyst was initially left untreated, following a watch-and-wait approach. However, three months later, the patient developed respiratory difficulties. The cyst had increased in size to 47×43×21 mm, with a volume of 55 mL. Consequently, the patient underwent a surgical resection in the operating room, which was completed without complications. The respiratory symptoms resolved immediately following the surgery (Figure 2).

Histological analysis (Figure 3) showed that the resected cyst was composed of four layers of tissue, which were the mucosa, the submucosa, the

Received: March 01, 2024

Accepted: May 04, 2024

Published online: June 04, 2024

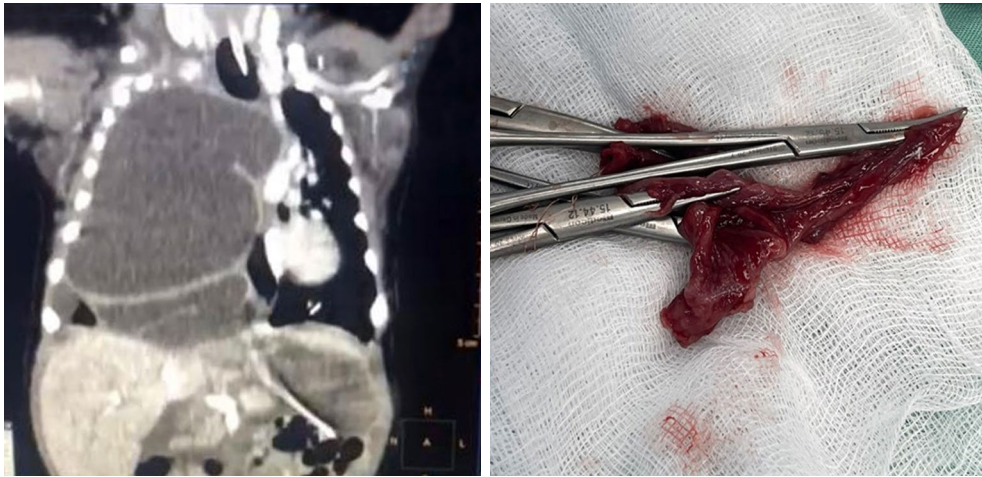Correspondence: María Fernanda Marenco Gutiérrez, MD.

E-mail: ma.fernandamarenco@yahoo.com

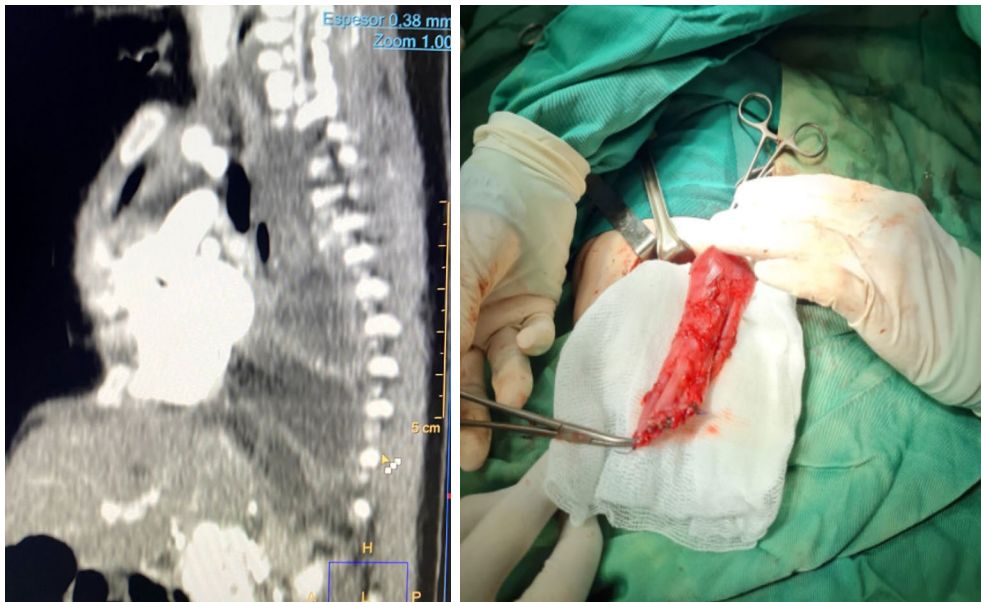
Department of Pediatric Surgery, Hospital Fernando Vélez Paiz, Managua, Nicaragua.

## Citation:

Gutiérrez MFM. Double esophageal duplication cysts: A rare case report in Nicaragua. Turkish J Ped Surg 2024;38(2):1-4. doi: 10.62114/JTAPS.2024.27.



**Figure 1.** Computed tomography demonstrates the integrity of the diaphragm and a cyst septate image 132×59×41 mm in size and 120 mL in volume, located extrapleurally near the right paravertebral. Intraoperative image of the esophageal duplication cyst; the cyst had a layer of muscle and was connected with an obliterated fistula to the esophagus.

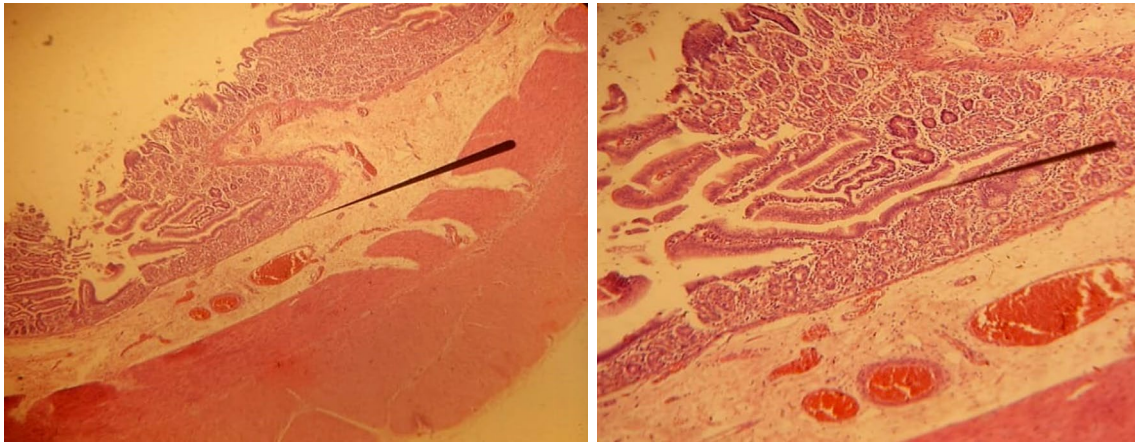


**Figure 2.** Computed tomography demonstrates the second cyst 47×43×21 mm in size and 55 mL in volume, located extrapleurally near the right paravertebral area. A layer of muscle is visible in the intraoperative image of the second esophageal duplication cyst.

muscularis propria, and either the serosa or adventitia, compatible with esophageal tissue. An ultrasound conducted at the six-month follow-up revealed no signs of disease, residual tissue, or recurrence. Our patient represents the fourth case of this condition reported worldwide.

## DISCUSSION

Esophageal duplication cysts are uncommon congenital cystic masses that arise from an error in foregut budding during the fifth to eighth week of embryonic development, a process known as



**Figure 3.** Photomicrographs of the surgically resected neonate esophageal duplication cyst. Pathologic examination showed an internal layer with pseudostratified ciliated epithelium (H&E,  $\times 400$ ), covered by layers of smooth muscle and striated muscle.

vacuolization.<sup>[1-3]</sup> During this phase, the primitive foregut splits into dorsal and ventral segments. The dorsal segment evolves into the esophagus, while the ventral segment forms the tracheobronchial tree.<sup>[1-3]</sup>

Foregut budding error may lead to bronchogenic cyst, esophageal duplication cyst, or bronchopulmonary foregut malformations (BPFM), a term proposed in 1968 by Gerle<sup>[4]</sup> to encompass the full spectrum of developmental aberrations of the embryonic foregut. The presence of an accessory lung bud distal to the normal lung bud has been proposed as the underlying basis of BPFM.<sup>[5]</sup> An interesting theory is that all BPFMs belong to a homogeneous group with a common embryologic pathogenesis. This group includes pulmonary sequestration, tracheoesophageal fistula, intestinal duplication cysts, neurenteric cysts, systemic arterializations of the lung, bronchogenic cysts, esophageal diverticula, and ectopic bronchial mucosal rests in the esophageal wall.<sup>[6]</sup>

Esophageal duplication cyst is one of the GI duplications that are rare congenital malformations occurring anywhere from the mouth to the anus. About 10 to 15% of all duplication cysts in the GI tract are esophageal.<sup>[6]</sup>

The histopathological criteria for classifying a foregut duplication cyst as an esophageal cyst were developed by Arbona et al.<sup>[7]</sup> as follows: the cyst is within or attached to the esophageal wall; it is covered by two muscle layers; the lining is squamous,

columnar, cuboidal, pseudostratified, or ciliated epithelium.

Esophageal duplication cysts are the second most common type of GI duplication cyst, following ileal duplication cysts. However, about 100 cases of esophageal duplication cysts have been documented to date. Esophageal duplication cysts typically occur as a solitary cyst, but there have been three reported instances of multiple (two) esophageal duplication cysts.<sup>[1,8,9]</sup>

The first known case of a double esophageal duplication cyst was reported by Robison et al.<sup>[10]</sup> in 1987. The second case was documented by Kang et al.<sup>[11]</sup> in 2008. This case report described multiple esophageal duplication cysts exhibiting varied pathological features, with the cysts lined by pseudostratified ciliated columnar and stratified squamous epithelium. These esophageal cysts were incidentally discovered in a 53-year-old male during treatment for pneumonia. The third case was encountered in China in 2013 and was reported by Zhang et al.<sup>[9]</sup> as double esophageal duplication cysts containing ectopic gastric mucosa. They reported a three-year-old patient with one cyst measuring 10 cm and the other 1 cm. The patient in this report appears to be the fourth documented case of multiple esophageal duplication cysts. In the first two cases, the cysts were completely removed. Zhang et al.<sup>[9]</sup> performed a complete removal of the larger cyst while adopting a watch-and-wait approach for the second cyst; similarly, a watch-and-wait approach



was initially applied to the smaller cyst in our case, but it was later removed during a subsequent surgery.

In conclusion, this report described a very rare case of a newborn with thoracic esophageal duplication cyst that was found at birth. Compression of the atrium and respiratory distress were the signs and symptoms. Scanning at three months allowed complete resolution of the double duplication. According to the other three case reports in the literature and our case, breathing difficulties caused by external compression commonly occur in thoracic esophageal duplication. We assume that thoracic esophageal duplication cysts should be included in the differential diagnosis of an infant with respiratory distress and prenatal diagnosis of congenital diaphragmatic hernia. Definitive diagnosis is based on histopathological findings, and surgical removal of the cyst is the treatment of choice.

**Patient Consent for Publication:** A written informed consent was obtained from the parent of the patient.

**Data Sharing Statement:** The data that support the findings of this study are available from the corresponding author upon reasonable request.

**Conflict of Interest:** The authors declared no conflicts of interest with respect to the authorship and/or publication of this article.

**Funding:** The authors received no financial support for the research and/or authorship of this article.

## REFERENCES

1. Rico-Morales MM, Ferrer-Márquez M, Belda-Lozano R, Yagüe-Martín E, Felices-Montes M, Rubio-Gil F. Esophageal duplication cyst as an unusual cause of adult dysphagia. *Cir Esp* 2007;82:361-3. doi: 10.1016/s0009-739x(07)71748-7.
2. Alsinan TA, Altokhais TI. Multiple thoracic and abdominal foregut duplication cysts: A case report. *World J Clin Cases* 2024;12:1504-9. doi: 10.12998/wjcc.v12.i8.1504.
3. Chan M, Zavala SR. Esophageal Cyst. 2023 Jul 4. In: StatPearls [Internet]. Treasure Island (FL): StatPearls Publishing; 2024.
4. Gerle RD, Jaretzki A 3rd, Ashley CA, Berne AS. Congenital bronchopulmonary-foregut malformation. Pulmonary sequestration communicating with the gastrointestinal tract. *N Engl J Med* 1968;278:1413-9. doi: 10.1056/NEJM196806272782602.
5. Nobuhara KK, Gorski YC, La Quaglia MP, Shamberger RC. Bronchogenic cysts and esophageal duplications: Common origins and treatment. *J Pediatr Surg* 1997;32:1408-13. doi: 10.1016/s0022-3468(97)90550-9.
6. Stringel G, Mercer S, Briggs V. Esophageal duplication cyst containing a foreign body. *Can Med Assoc J* 1985;132:529-31.
7. Arbona JL, Fazzi JG, Mayoral J. Congenital esophageal cysts: Case report and review of literature. *Am J Gastroenterol* 1984;79:177-82.
8. Wahi JE, Safdie FM. Esophageal duplication cysts: A clinical practice review. *Mediastinum* 2023;7:1. doi: 10.21037/med-22-33.
9. Zhang Z, Jin F, Wu H, Tan S, Tian Z, Cui Y. Double esophageal duplication cysts, with ectopic gastric mucosa: A case report. *J Cardiothorac Surg* 2013;8:221. doi: 10.1186/1749-8090-8-221.
10. Robison RJ, Pavlina PM, Scherer LR, Grosfeld JL. Multiple esophageal duplication cysts. *J Thorac Cardiovasc Surg* 1987;94:144-7.
11. Kang CU, Cho DG, Cho KD, Jo MS. Thoracoscopic stapled resection of multiple esophageal duplication cysts with different pathological findings. *Eur J Cardiothorac Surg* 2008;34:216-8. doi: 10.1016/j.ejcts.2008.04.019.