



Surgical approach and antireflux surgery results in gastroesophageal reflux disease in children with neurological deficit

Aybegum Kalyoncu Aycenk¹, Kivilcim Karadeniz Cerit², Nilay Bas Ikizoglu³, Emrullah Tolga Dagli², Gursu Kiyan²

Cerebral palsy (CP) is a neurological disorder affecting movement, muscle coordination, and posture. It is the most common cause of motor disability in children. Its prevalence is 4.4 per 1,000 live births in Türkiye.^[1] There may be prenatal, antenatal, and postnatal causes of CP, such as hypoxic ischemic events, infections, genetic causes, and preterm births. The incidence of gastroesophageal reflux disease (GERD) in children with CP is 40 to 75%.^[2,3] Individuals with CP have an increased risk of GERD for several reasons, including muscle tone and coordination issues, impaired swallowing reflex, delayed gastric emptying, postural challenges, and increased intra-abdominal pressure. The management of GERD in CP involves a combination of lifestyle modifications, dietary adjustments, medications (antisecretory and prokinetic agents), and surgery. The indication for antireflux surgery (ARS) in CP is resistance to medical treatment and the development of morbid GERD complications [recurrent aspiration

Abstract

Objectives: The study aimed to evaluate the surgical results of antireflux surgery (ARS) in neurologically impaired children with gastroesophageal reflux disease (GERD) who underwent surgery in our clinic.

Patients and methods: This retrospective study included 84 children (50 males and 34 females; mean age: 44.4±49 months; range, 2 to 224 months) between January 2011 and October 2016. Data on patient demographics, indications for surgery, preoperative symptoms, preoperative diagnostic tests, surgical procedures, complications, and reoperations were collected.

Results: The mean follow-up period was 17.9±22.5 months. The most frequent underlying pathology was cerebral palsy (67.4%). The main indication was recurrent aspiration pneumonia (77.1%). Preoperative diagnostic tests included an upper gastrointestinal contrast study (78.6%), gastric emptying study (69%), 24-h pH monitoring (21.4%), and endoscopy (8.3%). Surgical procedures included laparoscopic Nissen fundoplication (LNF) and gastrostomy in 61 patients, only LNF in 12 patients, and open Nissen fundoplication and gastrostomy in five patients. Laparoscopic Nissen fundoplication and pyloroplasty were performed in three patients, and LNF, gastrostomy, and pyloroplasty were performed in three patients. In the postoperative period, 58.3% of patients were free of symptoms. Postoperative complications occurred in six patients. A redo Nissen fundoplication was performed in four patients. Three of these patients were diagnosed with a postoperative hiatal hernia. However, the wrap was intact in all three of them. One patient had a laryngotracheoesophageal cleft anomaly and underwent redo surgery. One patient died in the early postoperative period owing to nonsurgical reasons. Seventeen patients died due to nonsurgical reasons.

Conclusion: The indications and postoperative results of ARS in children with cerebral palsy are controversial. According to our results, the main indication for ARS was recurrent aspiration pneumonia, which decreased dramatically in the postoperative period. Long-term results suggest that 58.3% of our patients did not have any complaints and benefited from surgical treatment. Antireflux surgery is an effective and safe treatment for GERD in children with neurological deficits.

Keywords: Antireflux surgery, gastric emptying scintigraphy, gastroesophageal reflux, neurological deficit, pyloroplasty.

Received: March 23, 2024

Accepted: May 22, 2024

Published online: July 03, 2024

Correspondence: Aybegum Kalyoncu Aycenk, MD.

E-mail: aybegumkalyoncu@gmail.com

¹Department of Pediatric Surgery, Ordu University Faculty of Medicine, Ordu, Türkiye

²Department of Pediatric Surgery, Marmara University Faculty of Medicine, İstanbul, Türkiye

³Department of Pediatric Pulmonology, İstanbul University İstanbul Faculty of Medicine, İstanbul, Türkiye

Citation:

Aycenk AK, Cerit KK, Bas Ikizoglu N, Dagli ET, Kiyan G. Surgical approach and antireflux surgery results in gastroesophageal reflux disease in children with neurological deficit. Turkish J Ped Surg 2024;38(2):1-6. doi: 10.62114/JTAPS.2024.33.

pneumonia (RAP), severe growth retardation, severe esophagitis, and esophageal stricture]. The most common surgical technique for GERD is Nissen fundoplication.^[4] The risk factors for postoperative recurrence in GERD are age <6 years, accompanying neurological deficits (ND), preoperative hiatal hernia, postoperative dysphagia with dilatation requirement, and postoperative retching.^[5] This study aimed to discuss the surgical technique, complications, mortality, and morbidity in children with CP who were diagnosed with GERD in our clinic.

PATIENTS AND METHODS

This retrospective single-center study included 84 patients (50 males and 34 females; mean age: 44.4±49 months; range, 2 to 224 months; median age: 48 months) with ND who underwent surgery for GERD at the Marmara University Pendik Training and Research Hospital, Department of Pediatric Surgery between January 2011 and October 2016. A single surgeon performed all procedures. In the preoperative period, we preferred to use upper gastrointestinal contrast studies for the diagnosis of GERD to evaluate the preoperative anatomy and gastric emptying scintigraphy to decide on the surgical technique. However, owing to the special and fragile nature of the patient group, there were instances where tests were canceled before or during the examination.

The technique of choice for ARS was Nissen fundoplication. The operation included three steps in each case as follows: (i) dissection of the phrenoesophageal membrane, (ii) hiatal repair, and (iii) fundoplication of a 360° wrap using nonabsorbable sutures (Figures 1-3).

It was performed with five trocars using a laparoscopic method. Laparoscopy-guided percutaneous gastrostomy was performed in patients with indications for gastrostomy using the initial placement kit. Heineke-Mikulicz pyloroplasty was performed in patients with an indication for pyloroplasty. The indications for ARS were discussed and decided upon in pediatric surgical patient councils. The indications for pyloroplasty were determined by councils involving pediatric gastroenterology and, if necessary, pediatric pulmonology.

RESULTS

Twenty-nine (34.5%) patients were younger than one year of age. Eighty-four patients were followed for at least three years (range, six months to four

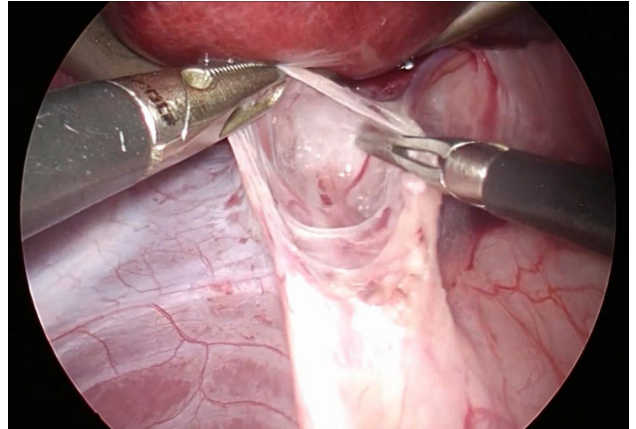


Figure 1. Dissection of the phrenoesophageal membrane.

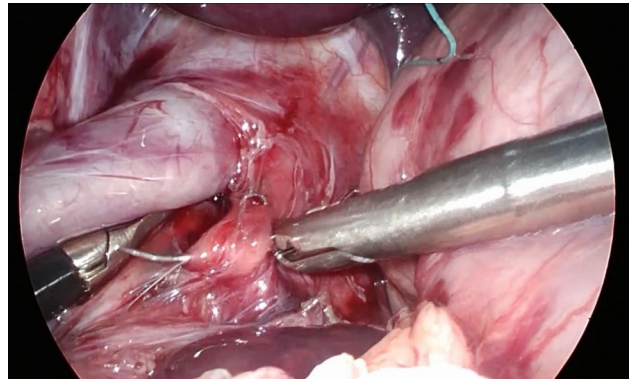


Figure 2. Hiatal repair.

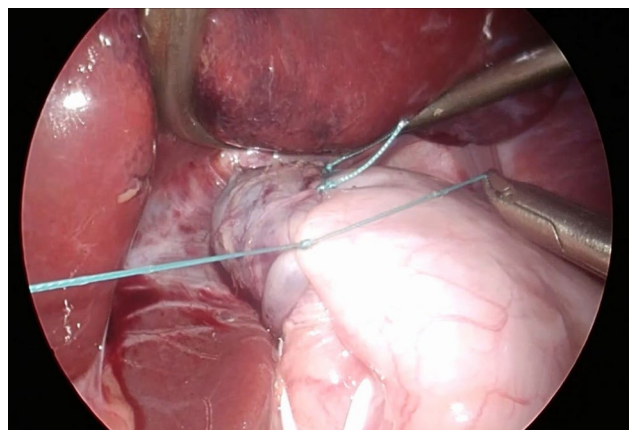


Figure 3. Fundoplication.

years). Fifty-six (67.4%) patients had CP, seven (8.4%) patients had West syndrome, and 20 patients were diagnosed with other underlying neurological problems, such as different types of myopathies and neurodegenerative diseases, periventricular leukomalacia, neuronal lipofuscinosis syndrome, Crouzon syndrome, Freeman-Sheldon syndrome, cerebro-oculo-facio-skeletal syndrome, and Pallister-Killian syndrome. Concomitant nonneurological diseases included Jeune syndrome, laryngotracheoesophageal cleft, laryngomalacia, congenital heart disease, respiratory distress syndrome, and Pierre Robin syndrome.

The patients received medical treatment for a mean of 11.8 ± 14 months before surgery. Preoperative complaints were RAP in 64 (77.1%) patients, swallowing difficulties in 53 (63.8%) patients, growth and developmental retardation in 14 (16.8%) patients, vomiting in 21 (25.3%) patients, and chronic cough in one (1.2%) patient.

Sixty-six (78.5%) patients had preoperative upper gastrointestinal contrast studies. Physiological findings were detected in 24 (36.4%) patients, reflux up to the distal esophagus in 10 (15.2%) patients, reflux in the middle esophagus in six (9.1%) patients, and reflux up to the proximal esophagus in 26 (39%) patients.

Preoperative gastric emptying studies were performed in 58 (69%) patients (liquid food and technetium for 60 min). In 27 patients (46.5%), the gastric half emptying time ($T_{1/2}$) was <60 min, and multiple reflux episodes were observed in 20 cases. In 31 (53.4%) patients, $T_{1/2}$ was between 60 and 120 min, and multiple reflux episodes were observed in 29 patients. In seven (12.1%) patients, $T_{1/2}$ was over 120 min, and multiple reflux episodes were observed in five cases.

Twenty-four-hour pH monitoring was performed in 17 patients. The pH reflux index represents the proportion of time during which esophageal pH was <4 . A reflux index exceeding 4% was considered a positive test result for pH monitoring. Pathological reflux was observed in 14 of the 17 patients in the evaluation.

Endoscopy was performed in seven (8.3%) patients. Endoscopy results showed severe esophagitis in three patients, ulcerative patches in one patient, chronic gastritis and esophagitis in one patient, and peptic

esophageal stricture in two patients. A history of recurrent upper gastrointestinal bleeding was present in the three patients with severe esophagitis.

Laparoscopic Nissen fundoplication (LNF) and laparoscopy-assisted gastrostomy (LAG) were performed in 61 (72.6%) patients. Five (5.9%) patients underwent open Nissen fundoplication (ONF) and gastrostomy. Three of these ONFs were decided due to the patient's previous surgical operations ($n=3$), patient's anatomical reasons ($n=1$), and redo Nissen operation ($n=1$). Twelve (14.2%) patients underwent surgery with LNF, with no indication for gastrostomy. Laparoscopic Nissen fundoplication and pyloroplasty were performed in three (3.5%) patients. Laparoscopic Nissen fundoplication, LAG, and pyloroplasty were performed in three (3.5%) patients (Figure 4).

Gastric emptying scintigraphy, in addition to demonstrating GERD, is a test where we measure gastric emptying time, and it is used to discuss the indication of adding pyloroplasty to the surgery. In patients with prolonged gastric emptying time, pyloroplasty is added if the patient's clinical presentation also supports prolonged gastric emptying time. However, the indications have been limited since surgery alters both anatomy and physiology. The indication for pyloroplasty was discussed if the patient's gastric emptying was longer than 120 min and was accompanied by other symptoms, such as retching, vomiting, and post-feeding abdominal distension. In one patient, the procedure started laparoscopically but had to be converted to an open approach due to anatomical challenges.

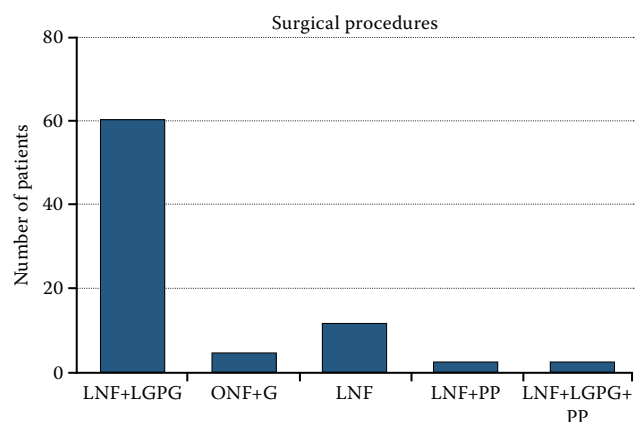


Figure 4. Types of surgical procedures.

LNF: Laparoscopic Nissen fundoplication; LGPG: Laparoscopy guided percutaneous gastrostomy; ONF: Open Nissen fundoplication; G: Gastrostomy; PP: Pyloroplasty.

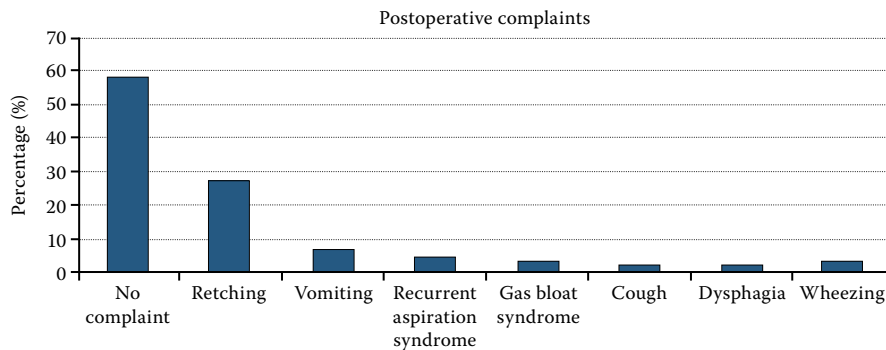


Figure 5. Postoperative complaints.

During the postoperative follow-up period of 84 patients, 49 (58%) patients did not have any postoperative complaints. Twenty (23.8%) patients complained of retching, six (7.1%) patients complained of vomiting, four (4.8%) patients had RAP, three patients had gas-bloat syndrome, two patients had dysphagia, and two patients had wheezing (Figure 5). Hiatal hernia was detected in three patients, and postoperative complaints were not observed in two of these patients. In one of them, vomiting started in the second month.

Only one patient died in the early postoperative period owing to nonsurgical reasons. Early postoperative complications were observed in four patients. Two patients had LNF and LAG in the postoperative period of fever that was treated with broad-spectrum antibiotics, one had gastrostomy leakage, and one had intussusception that was surgically treated. Late postoperative complications were observed in six (7.1%) patients. Hiatal hernia was observed in three cases in which the LNF and LAG were performed with fundoplication intact; however, a part of the fundus herniated posterior

to the esophagus. All patients underwent redo fundoplication. Dysphagia was observed in three patients who underwent LNF. The patients were treated with esophageal balloon dilatation of the wrap. No recurrences or herniations were observed in these patients (Table 1). Seventeen patients died due to nonsurgical reasons during the mean follow-up period of 17.9 ± 22.5 months (21%).

DISCUSSION

Cerebral palsy is one of the most common causes of NDs in the pediatric population.^[1] The incidence of GERD in children with CP varies between 40 and 75%.^[2,3] Most patients with ARS are children with neurological problems.^[4] Indications, preoperative tests, surgical techniques, early and late complications, and results of surgery are topics that have been debated about ARS in children with NDs. In the literature, even in the NASPGHAN and ESPGHAN guidelines, diagnostic tests, investigations, and treatment recommendations vary according to patient and clinical factors.^[6]

TABLE 1 Complications		
Early complications	Patient (n)	
Postoperative fever	2	Broad-spectrum intravenous antibiotic treatment
Gastrostomy leakage	1	Reoperated
Intussusception	1	Operated
Late complications		
Hiatus hernia	3	Redo fundoplication
Dysphagia	3	Esophageal balloon dilatation

Recurrent aspiration pneumonia is the most common cause of mortality, morbidity, and poor quality of life in these patients.^[7] The most important causes of RAP are oropharyngeal dysphagia and GERD in patients with CP. The risk of death from respiratory diseases is 14 times higher in adults with CP than in the general population.^[8] Recurrent aspiration pneumonia causes lung damage and chronic lung disease in these patients.^[9,10] In this regard, the control of RAP is an important result of this treatment. In a study by Srivastava et al.,^[11] with the participation of 42 children's hospitals in the USA, RAP was observed at least once in the preoperative period in 3,721 (55%) patients. After ARS was performed in these patients, a significant decrease in GERD recurrence and mechanical ventilation requirement was observed. In our series, we discuss the results of ARS operations performed on 84 children with NDs. Although the rate of RAP, which was the main complaint and indication for surgery, was 77.1% in the preoperative period, this rate decreased to 4.8% after surgery. We believe that one of the factors influencing this result in our series was the addition of gastrostomy to the majority of patients who underwent ARS. The results of this study will contribute significantly to the literature by demonstrating that ARS in children with NDs is an important and effective option in the treatment of RAP. Long-term results suggest that 58.3% of our patients did not have any complaints and did not benefit from treatment in our series.

Surgical treatment is successful in 90% of neurologically normal children with GERD, but the reported failure rate is relatively high in children with NDs.^[9] In our study, the rates of early and late complications were 11.9%. Among those with late complications, three (3.5%) patients developed postoperative hiatal hernia. However, when upper gastrointestinal contrast studies were examined, we saw that the wrap was not herniated, and the wrap was intact, but the stomach fundus was herniated behind the esophagus. The relationship between hiatus hernia and minimal esophageal dissection has been demonstrated in consecutive studies published by St. Peter et al.^[10,12,13] These studies have shown that when esophageal dissection/mobilization is minimized, the risk of wrap herniation and reoperation is reduced. As mentioned in the literature, our study also suggests that crural repair and minimal dissection of the phrenoesophageal ligament are

important in the occurrence of low-rate wrap failure and hiatus hernia.

In the pyloroplasty and fundoplication series of Masqusi and Velanovich,^[13] complaints of patients with preoperative gas-bloat syndrome and gastric emptying over 120 min decreased significantly in the postoperative period. Ceriati et al.^[14] have recommended performing pyloroplasty simultaneously with fundoplication surgery when there is delayed gastric emptying observed in gastric emptying scintigraphy. They emphasized the importance of this in achieving "tension-free" Nissen fundoplication. In our study, patients with gastric emptying scintigraphy results of 120 min or more were indicated for pyloroplasty if they were symptomatic. Pyloroplasty was performed in six patients. During the postoperative period, a hiatus hernia was detected in one of these patients after resistant vomiting symptoms, and no postoperative complaints were detected in the other five patients.

In the context of pediatric surgery, there is a decreasing trend in preference for ARS. The elevated rates of mortality, morbidity, surgical complications, and reoperation contribute to the hesitancy among surgeons in performing this procedure.^[15,16] We believe that one significant reason for this trend is the advancement of medical treatment options, and another reason is that there is no longer an indication for performing prophylactic ARS in addition to gastrostomy in children requiring gastrostomy.

In the meta-analysis by Di Lorenzo and Orenstein,^[15] data from 15 separate studies were examined. The findings reported recurrence rates ranging from 0 to 39%, dysphagia rates from 0 to 50%, and gas-bloat syndrome rates from 0 to 50%. In a study by Wockenforth et al.,^[17] which included 230 pediatric patients with CP and gastrostomy, the five-year survival rate after fundoplication was 59%.

First of all, this study has a limited patient population and the follow-up period is short due to the difficult quality of life of cerebral palsy patients and their families, mobility restrictions and partially short patient survival.

In conclusion, we examined our antireflux series in a specific group of children with NDs. We believe that the results of this study are significant from a surgical perspective as they contain important technical recommendations. For instance, crural repair and minimal dissection of the phrenoesophageal ligament

are crucial in reducing the occurrence of low-rate wrap failure and hiatus hernia, and the addition of a gastrostomy procedure reduce postoperative complication risks. The indications for pyloroplasty were also discussed in this study, and a significant decrease in RAP was observed. Gastroesophageal reflux disease is a frequently encountered problem in children with NDs and is associated with a high mortality rate. According to our study, ARS is an effective and safe treatment for GERD in children with NDs, as it significantly reduces RAP.

Ethics Committee Approval: The study protocol was approved by the Marmara University Faculty of Medicine Clinical Research Ethics Committee (date: 07.10.2016., no: 09.2016.496). The study was conducted in accordance with the principles of the Declaration of Helsinki.

Patient Consent for Publication: A written informed consent was obtained from the parents and/or legal guardians of the patients.

Data Sharing Statement: The data that support the findings of this study are available from the corresponding author upon reasonable request.

Author Contributions: Idea/concept, control/supervision, references and fundings: G.K.; Design, materials: G.K., A.K.A.; Data collection and/or processing, writing the article: A.K.A.; Analysis and/or interpretation: A.K.A., K.K.C.; Literature review: A.K.A., N.B.I.; Critical review: : A.K.A., G.K., E.T.D.

Conflict of Interest: The authors declared no conflicts of interest with respect to the authorship and/or publication of this article.

Funding: The authors received no financial support for the research and/or authorship of this article.

REFERENCES

- Serdaroğlu A, Cansu A, Ozkan S, Tezcan S. Prevalence of cerebral palsy in Turkish children between the ages of 2 and 16 years. *Dev Med Child Neurol* 2006;48:413-6. doi: 10.1017/S0012162206000910.
- Gustafsson PM, Tibbling L. Gastro-oesophageal reflux and oesophageal dysfunction in children and adolescents with brain damage. *Acta Paediatr* 1994;83:1081-5. doi: 10.1111/j.1651-2227.1994.tb12990.x.
- Pensabene L, Miele E, Del Giudice E, Strisciuglio C, Staiano A. Mechanisms of gastroesophageal reflux in children with sequelae of birth asphyxia. *Brain Dev* 2008;30:563-71. doi: 10.1016/j.braindev.2008.01.009.
- Esposito C, Van Der Zee DC, Settini A, Doldo P, Staiano A, Bax NM. Risks and benefits of surgical management of gastroesophageal reflux in neurologically impaired children. *Surg Endosc* 2003;17:708-10. doi: 10.1007/s00464-002-9170-6.
- Kimber C, Kiely EM, Spitz L. The failure rate of surgery for gastro-oesophageal reflux. *J Pediatr Surg* 1998;33:64-6. doi: 10.1016/s0022-3468(98)90363-3.
- Rosen R, Vandenplas Y, Singendonk M, Cabana M, DiLorenzo C, Gottrand F, et al. Pediatric gastroesophageal reflux clinical practice guidelines: Joint recommendations of the North American Society for Pediatric Gastroenterology, Hepatology, and Nutrition and the European Society for Pediatric Gastroenterology, Hepatology, and Nutrition. *J Pediatr Gastroenterol Nutr* 2018;66:516-54. doi: 10.1097/MPG.0000000000001889.
- Marpole R, Blackmore AM, Gibson N, Cooper MS, Langdon K, Wilson AC. Evaluation and management of respiratory illness in children with cerebral palsy. *Front Pediatr* 2020;8:333. doi: 10.3389/fped.2020.00333.
- Ryan JM, Peterson MD, Ryan N, Smith KJ, O'connell NE, Liverani S, et al. Mortality due to cardiovascular disease, respiratory disease, and cancer in adults with cerebral palsy. *Dev Med Child Neurol* 2019;61:924-8. doi: 10.1111/dmcn.14176.
- Cheung KM, Tse HW, Tse PW, Chan KH. Nissen fundoplication and gastrostomy in severely neurologically impaired children with gastroesophageal reflux. *Hong Kong Med J* 2006;12:282-8.
- St Peter SD, Poola A, Adibe O, Juang D, Fraser JD, Aguayo P, et al. Are esophagocrural sutures needed during laparoscopic fundoplication: A prospective randomized trial. *J Pediatr Surg* 2017;S0022-3468(17)30630-9. doi: 10.1016/j.jpedsurg.2017.10.008.
- Srivastava R, Berry JG, Hall M, Downey EC, O'Gorman M, Dean JM, et al. Reflux related hospital admissions after fundoplication in children with neurological impairment: Retrospective cohort study. *BMJ* 2009;339:b4411. doi: 10.1136/bmj.b4411.
- Ergun E, Gollu G, Ates U, Yagmurlu A. Minimal esophagus dissection without approximating the hiatus in laparoscopic fundoplication in pediatric population. *North Clin Istanbul* 2021;8:222-225. doi: 10.14744/nci.2020.10693.
- Masqusi S, Velanovich V. Pyloroplasty with fundoplication in the treatment of combined gastroesophageal reflux disease and bloating. *World J Surg* 2007;31:332-6. doi: 10.1007/s00268-006-0723-z.
- Ceriatı E, Marchetti P, Caccamo R, Adorisio O, Rivosecchi F, De Peppo F. Nissen fundoplication and combined procedures to reduce recurrence of gastroesophageal reflux disease in neurologically impaired children. *Sci Rep* 2020;10:11618. doi: 10.1038/s41598-020-68595-x.
- Di Lorenzo C, Orenstein S. Fundoplication: Friend or foe? *J Pediatr Gastroenterol Nutr* 2002;34:117-24. doi: 10.1097/00005176-200202000-00005.
- Wockenforth R, Gillespie CS, Jaffray B. Survival of children following Nissen fundoplication. *Br J Surg* 2011;98:680-5. doi: 10.1002/bjs.7415.
- Jancelewicz T, Lopez ME, Downard CD, Islam S, Baird R, Rangel SJ, et al. Surgical management of gastroesophageal reflux disease (GERD) in children: A systematic review. *J Pediatr Surg* 2017;52:1228-38. doi: 10.1016/j.jpedsurg.2016.09.072.