

A giant ovarian serous cystadenoma associated with multifollicular ovarian morphology in an adolescent girl

Eda Çingil¹, Gonca Gerçel¹, Elif Yaşar², Çiğdem Dicle Arıcan³, Furkan Adem Canbaz¹, Sefa Sağ¹

The management of large ovarian cysts in children poses challenges due to limited knowledge about their natural progress.^[1] These cysts are categorized by size, aiding healthcare professionals in evaluating their significance and determining the appropriate course of action. Cysts under 3 cm are typically physiologic cysts, are considered normal, and usually resolve without intervention. When a cyst exceeds 5 cm, it is deemed an enlarged cyst. Such cysts are at a higher risk of complications, including rupture or causing ovarian torsion. Cysts larger than 15 cm are classified as giant cysts.^[2,3]

Surgical intervention is recommended for cysts that show symptoms, continue to grow, or do not decrease in size over time. Some authors recommend surgery for ovarian cysts larger than 5 cm in asymptomatic patients to prevent potential complications of cysts.^[4,5] Various surgical options are available, ranging from less invasive procedures such as percutaneous or laparoscopic aspiration, laparoscopic unroofing, or resection, to more invasive techniques involving cystectomy by laparotomy.^[6]

Received: March 03, 2024

Accepted: June 24, 2024

Published online: July 03, 2024

Correspondence: Gonca Gerçel, MD.

E-mail: goncagercel@gmail.com

¹Department of Pediatric Surgery, Sancaktepe Şehit Prof. Dr. İlhan Varank Training and Research Hospital, İstanbul, Türkiye

²Department of Radiology, Sancaktepe Şehit Prof. Dr. İlhan Varank Training and Research Hospital, İstanbul, Türkiye

³Department of Pathology, Sancaktepe Şehit Prof. Dr. İlhan Varank Training and Research Hospital, İstanbul, Türkiye

Citation:

Çingil E, Gerçel G, Yaşar E, Arıcan ÇD, Canbaz FA, Sağ S. A giant ovarian serous cystadenoma associated with multifollicular ovarian morphology in an adolescent girl. Turkish J Ped Surg 2024;38(2):1-6. doi: 10.62114/JTAPS.2024.29

Abstract

Large ovarian cysts, regardless of whether benign or malignant, are uncommon and pose significant challenges in their management. This report discusses an adolescent diagnosed with a giant ovarian serous cystadenoma associated with a multifollicular ovarian morphology. A 17-year-old female patient was referred to us by a pediatrician due to abdominal distention and hirsutism. The physical examination showed that the patient reached Tanner Stage 5 development, indicating full maturity. There was noticeable abdominal distention and no organomegaly. Laboratory tests were unremarkable. Abdominopelvic ultrasonography and computed tomography were reported as a large cystic structure with thick walls and no septations, measuring 31.8×24.9×12.1 cm, possibly originating from the right ovary. The cyst was completely excised by laparotomy, while the ovarian tissue was preserved. It was observed that both ovaries had a multifollicular structure. Histopathological examination of the cyst was reported as a serous cystadenoma, which is a benign ovarian tumor. The latest follow-up of the patient was at six months after surgery, and the course of the follow-up was uneventful. The patient's follow-up is still ongoing. In childhood and adolescence, ovarian masses are mostly benign regardless of their size, and ovarian-sparing surgery should be considered the first treatment option.

Keywords: Child, cyst, ovary, serous cystadenoma.

The primary goal of these procedures is to preserve as much ovarian tissue as possible and reduce the risk of recurrence while maintaining fertility and hormonal functions. Ovarian tissue-conserving strategies are crucial, particularly for young patients, to ensure future fertility and endocrine health.^[7,8]

The appearance of ovaries in adolescents can significantly vary, including patterns that are uniform and densely filled with tiny follicles and those displaying multiple cysts or numerous follicles.^[9]

The multifollicular pattern of the ovary is identified by either a standard or increased size of the ovary, with more than five follicles sized between 5 and 10 mm in diameter scattered throughout the ovarian tissue. Importantly, this pattern is not linked to hyperandrogenism.^[9] It is critical to differentiate this pattern from polycystic ovary syndrome (PCOS), as the multifollicular pattern does not automatically imply the presence of hyperandrogenism or any metabolic disorders, which are often associated with PCOS. This report discusses the case of a 17-year-old female patient with giant ovarian serous cystadenoma associated with a multifollicular ovarian morphology who underwent ovarian tissue-preserving surgery.

CASE REPORT

A 17-year-old female patient was referred to us by a pediatrician due to abdominal distention and hirsutism. The swelling had been progressively increasing for two years without any gastrointestinal complaints. The patient's medical history was unremarkable, with no prior illnesses, allergies, surgeries, or medication use. The patient's menstrual cycles occurred every 40 days without

any disturbances. The patient weighed 70 kg, and body mass index was 27.3 kg/m² (overweight). The patient's weight was in the 87th percentile for her age. The patient's height was 160 cm and in the 33rd percentile for her age and sex.

Physical examination revealed a Tanner Stage 5 development with no abdominal tenderness but notable distension and no signs of organomegaly. Hirsutism was evident, with facial, upper abdominal, and thigh hair, resulting in a Ferriman-Gallwey score of 7 to 8. No abnormalities were found in other systemic examinations.

On laboratory tests, alpha-fetoprotein, beta-human chorionic gonadotropin, CA-125, and lactate dehydrogenase were normal. Diagnostic imaging via abdominopelvic ultrasonography (USG) and computed tomography revealed a large unilocular cystic lesion with a thick wall that was 31.8×24.9×12.1 cm and was presumed to originate from the right ovarian, extending into the upper quadrants. The midline cyst showed no solid components, papillary projections, or internal separations (Figures 1, 2). The left ovary was identifiable and distinct from the mass, but the right ovary remained obscured.

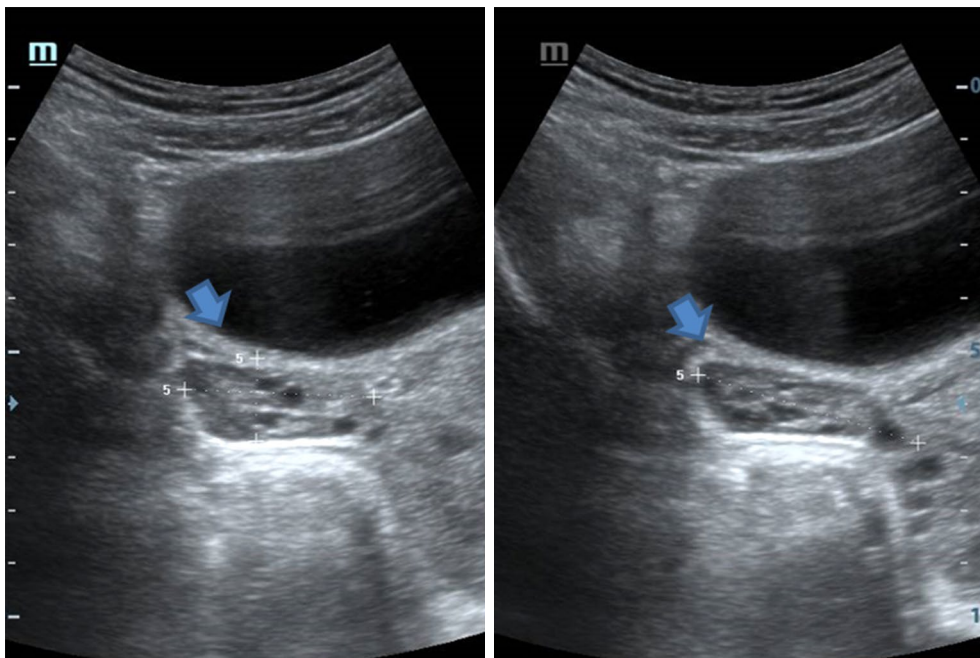


Figure 1. Left ovary with a multifollicular appearance on ultrasonography (arrow: ovarian structure).

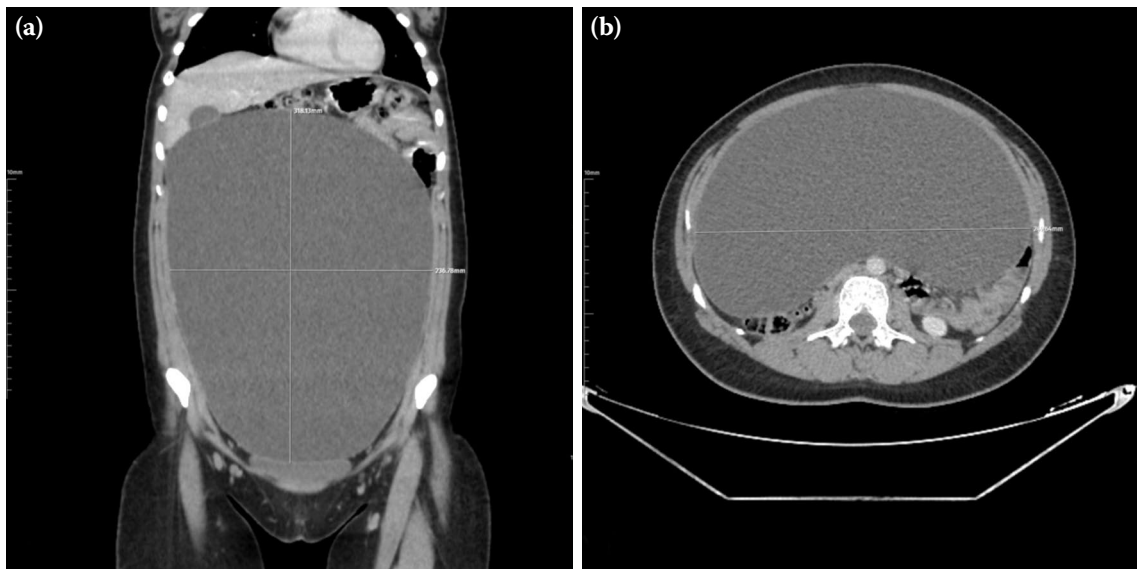


Figure 2. (a) Coronal and (b) axial computed tomography sections of a large unilocular cystic lesion originating from the right ovary.

A laparotomy with a midline vertical incision was performed. The procedure revealed a thin-walled cyst located just beneath the anterior abdominal wall. The cyst was fully mobilized and removed only after aspiration of approximately 3.7 L of clear, water-like serous fluid. This facilitated a clearer understanding of its anatomical connection to the right ovarian area. This aspiration significantly improved visibility and

reduced the mass's size, enabling precise removal. Subsequent examination during laparotomy revealed that both ovaries exhibited a multicystic follicular morphology with no signs of adenopathy or free abdominal fluid (Figure 3).

Histopathological analysis following the ovarian-sparing surgical removal confirmed the diagnosis of

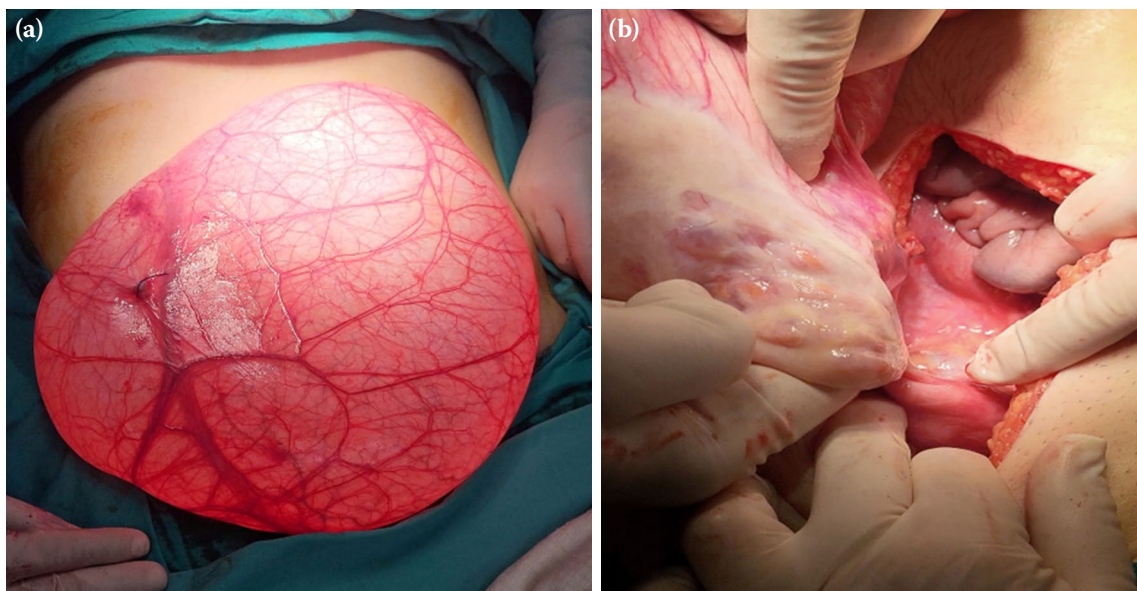


Figure 3. (a) Intraoperative appearance of the cyst originating from the right ovary, and (b) the multifollicular ovarian pattern.

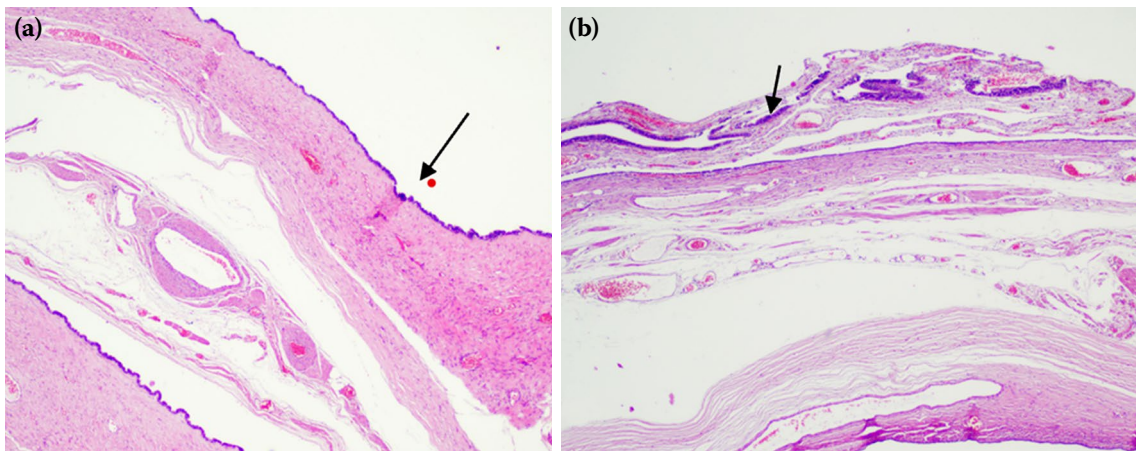


Figure 4. (a) Histopathologic sections show the wall structure of serous cystadenoma. In the area marked with an arrow, the luminal epithelium shows a single layer of cuboidal epithelium, some of which are pseudostratified (H&E, $\times 100$). (b) The area marked with an arrow on the cyst wall shows congested vascular structures and smaller cyst structures. Muscle fibers observed in mesonephric cysts in the differential diagnosis were absent in the cyst wall (H&E, $\times 100$).

ovarian serous cystadenoma, without malignant cells (Figure 4). The patient was discharged on the third postoperative day.

Initially weighing 70 kg, the patient's weight decreased to 60 kg after surgery, transitioning the body mass index from 27.3 kg/m^2 , classified as overweight, to a healthy weight category of 23.4 kg/m^2 . Preoperative assessments placed the weight-for-age in the 87th percentile, which adjusted to the 67th percentile following surgery. The latest follow-up of the patient was at six months after surgery, and the course of the follow-up was uneventful. The patient's follow-up is still ongoing. The follow-up USG examination after the surgery confirmed the preservation of the ovarian follicle structure.

DISCUSSION

The annual rate of ovarian neoplasms in girls and adolescents is estimated at 2.6 cases per 100,000 girls. They are usually benign, and the most frequent types are mucinous cystadenomas, mature teratomas, and serous cystadenomas.^[1] Giant ovarian serous cystadenomas are relatively rare in the adolescent population, and their asymptomatic nature further complicates timely diagnosis.^[1,5] However, when symptoms do occur, they can be nonspecific and may include abdominal distension and weight gain, as observed in the patient discussed. This ambiguity

in symptoms can make serous cystadenomas challenging to diagnose promptly, as they can easily be mistaken for other, more benign diseases. The presentation of such symptoms, particularly when persistent, necessitates further evaluation to rule out serous cystadenomas, among other potential diagnoses.

In evaluating adnexal masses via USG, certain findings can hint at the nature of the growth, distinguishing between benign tumors and potential malignancies.^[9] Features suggestive of benign tumoral growth include well-defined borders, the presence of a single compartment, a homogeneous internal structure, and the absence of solid components or minimal solid components that are nonnodular.^[1,8] In contrast, indicators of malignancy in adnexal masses might include irregular borders, multilocular solid masses with thick septations, solid nodules with significant blood flow observed during Doppler USG analysis, and the presence of ascites. These USG characteristics must be meticulously assessed, as they guide clinical decision-making, influencing the need for surgical intervention, the extent of such intervention, and the follow-up strategy.^[9,10] This detailed USG evaluation plays a pivotal role in the early detection and management of ovarian tumors, thereby impacting patient prognosis.

Literature indicates that while most ovarian masses in adolescents are benign, the size and

absence of symptoms do not preclude the possibility of malignancy.^[1,10,11] This necessitates a careful and thorough evaluation to avoid overlooking potential malignancies. The decision for surgical intervention, particularly ovarian-sparing surgery, is supported by these considerations, adapting with current recommendations for managing epithelial ovarian cancers in young patients.^[11,12] The American College of Obstetricians and Gynecologists also supports a conservative approach to ovarian masses in young female patients, advocating for fertility-preserving surgeries whenever malignancy is not a primary concern.^[8]

The management of giant ovarian cysts (>15 cm) in adolescents presents a unique set of challenges to the clinician, balancing between the immediate need for tumor removal and the long-term considerations of fertility preservation and hormonal function.^[5] As reported in the literature, although rare, the emergence of large ovarian masses without accompanying symptoms may also occur. Due to the large size of the mass and the potential risks of cyst rupture, malignancy, and tumoral spread, we planned a surgical strategy that would minimize damage while ensuring complete removal of the cyst. Therefore, the imperative to prevent its rupture during removal, a preliminary aspiration of some cyst fluid was undertaken. This strategic aspiration was aimed at reducing the cyst's volume, thereby facilitating complete and easier extraction of the cyst from the abdominal cavity without rupture. This approach underlines the careful balance between minimizing the risk of cyst rupture, which could disseminate cystic contents that may complicate the clinical scenario, and ensuring total removal of the cyst, which is a critical factor in both diagnostic and therapeutic management of such cases. In the present case, the successful preservation of ovarian tissue is important for maintaining endocrine function and preserving future fertility potential. The clear water-like structure of the aspiration material taken from the cyst during the operation and the thin-walled unilocular structure of the cyst gave clues that the cyst could be a serous cystadenoma.

In the presence of a multifollicular ovarian morphology associated with a giant serous cystadenoma, detailed diagnostic methods and treatment approaches are required. In the study by Holm et al.,^[13] which evaluated the pubertal maturation of internal genitalia using USG in 166

healthy girls, a multicystic ovary structure was observed in only five girls, and of these, only two fully met the criteria for PCOS. It is imperative to distinguish multifollicular ovarian morphology from PCOS, as it does not inherently indicate hyperandrogenism or metabolic dysfunction. In the literature, there is only one case report documenting the concurrent presence of PCOS and a giant serous ovarian cystadenoma.^[5] Additionally, another report describes the rare coexistence of a large ovarian mucinous cystadenoma with a contralateral teratoma and PCOS in an adolescent girl.^[14]

Postoperative follow-up revealed the preservation of the multifollicular ovarian morphology, indicating that the mass-induced stress did not influence this characteristic. In the study by Frederick et al.^[15] on the volume doubling time (VDT) of ovarian serous cystadenomas, it was found that 53.4% of these masses had a VDT of less than three years, while 15.1% exhibited a VDT between three and five years, and the remaining 31.5% either had a VDT of more than five years or showed no growth. Therefore, we believe that a healthy follow-up should last for at least five years.

In conclusion, the management of giant ovarian serous cystadenomas in adolescents necessitates a tailored approach that carefully balances the need for surgical intervention with the imperative to preserve fertility and hormonal function, particularly given the extended life expectancy of these young patients. In childhood and adolescence, ovarian masses are typically benign, irrespective of size. This fact emphasizes the critical importance of employing ovarian-preserving surgical techniques when treating adolescents with benign epithelial ovarian masses. Notably, these masses may exhibit a multifollicular ovarian pattern, which is a normal variant. Such an approach protects the patient's future reproductive and endocrine health while effectively managing the condition.

Patient Consent for Publication: A written informed consent was obtained from the parent of the patient.

Data Sharing Statement: The data that support the findings of this study are available from the corresponding author upon reasonable request.

Author Contributions: Study concept and design: E.Ç., G.G., S.S., E.Y., Ç.D.A.; Data collection: E.Ç., A.F.C.; Analysis and interpretation of data: E.Ç., G.G., S.S.; Drafting of the manuscript: E.Ç. All authors read and approved the final manuscript.

Conflict of Interest: The authors declared no conflicts of interest with respect to the authorship and/or publication of this article.

Funding: The authors received no financial support for the research and/or authorship of this article.

REFERENCES

1. Grigore M, Murarasu M, Himiniuc LM, Toma BF, Duma O, Popovici R. Large ovarian tumors in adolescents, a systematic review of reported cases, diagnostic findings and surgical management. *Taiwan J Obstet Gynecol* 2021;60:602-8. doi: 10.1016/j.tjog.2021.05.005.
2. Emeksiz HC, Derinöz O, Akkoyun EB, Güçlü Pınarlı F, Bideci A. Age-specific frequencies and characteristics of ovarian cysts in children and adolescents. *J Clin Res Pediatr Endocrinol* 2017;9:58-62. doi: 10.4274/jcrpe.3781.
3. Barragán-Curiel AE, Murillo-Zepeda C, Castro-Perez KF, Alcalá-Aguirre FO, Diaz-Montoya LS, Ruiz-Félix OA, et al. Giant mature ovarian cystic teratoma in a pediatric patient: Case report and literature review. *Case Rep Oncol* 2023;16:1066-72. doi: 10.1159/000534141.
4. Warner BW, Kuhn JC, Barr LL. Conservative management of large ovarian cysts in children: The value of serial pelvic ultrasonography. *Surgery* 1992;112:749-55.
5. Patel N, Dupuis G, Wild R. Giant ovarian cyst in an adolescent with PCOS. *Can Fam Physician* 2013;12:559-62.
6. Arena F, Romeo C, Castagnetti M, Scalfari G, Cimador M, Impellizzeri P, et al. Is the stripping technique a tissue-sparing procedure in large simple ovarian cysts in children? *J Pediatr Surg* 2008;43:1353-7. doi: 10.1016/j.jpedsurg.2007.11.014.
7. Canlorbe G, Chabbert-Buffet N, Uzan C. Fertility-sparing surgery for ovarian cancer. *J Clin Med* 2021;10:4235. doi: 10.3390/jcm10184235.
8. Dodge JE, Covens AL, Lacchetti C, Elit LM, Le T, Devries-Aboud M, et al. Management of a suspicious adnexal mass: A clinical practice guideline. *Curr Oncol* 2012;19:e244-57. doi: 10.3747/co.19.980.
9. Thaweekul P, Thaweekul Y, Mairiang K. A huge ovarian mucinous cystadenoma associated with contralateral teratoma and polycystic ovary syndrome in an obese adolescent girl. *Asia Pac J Clin Nutr* 2016;25:920-3. doi: 10.6133/apjcn.092015.49.
10. Łuczak J, Bağlaj M. Selecting treatment method for ovarian masses in children - 24 years of experience. *J Ovarian Res* 2017;10:59. doi: 10.1186/s13048-017-0353-0.
11. Özcan R, Kuruoğlu S, Dervişoğlu S, Eliçevik M, Emir H, Büyükkünel C. Ovary-sparing surgery for teratomas in children. *Pediatr Surg Int* 2013;29:233-7. doi: 10.1007/s00383-012-3228-x.
12. Tarca E, Trandafir LM, Cojocaru E, Costea CF, Rosu ST, Butnariu LI, et al. Diagnosis difficulties and minimally invasive treatment for ovarian masses in adolescents. *Int J Womens Health* 2022;14:1047-57. doi: 10.2147/IJWH.S374444.
13. Holm K, Laursen EM, Brocks V, Müller J. Pubertal maturation of the internal genitalia: An ultrasound evaluation of 166 healthy girls. *Ultrasound Obstet Gynecol* 1995;6:175-81. doi: 10.1046/j.1469-0705.1995.06030175.x.
14. Carmina E, Oberfield SE, Lobo RA. The diagnosis of polycystic ovary syndrome in adolescents. *Am J Obstet Gynecol* 2010;203:201.e1-5. doi: 10.1016/j.ajog.2010.03.008.
15. Frederick RP, Patel AG, Young SW, Dahiya N, Patel MD. Growth rate of ovarian serous cystadenomas and cystadenofibromas. *J Ultrasound Med* 2021;40:2123-30. doi: 10.1002/jum.15597.