

First results of laser treatment in our pediatric burn patients

Sabriye Dayi , Beyza Dede , Selenay İşçimen , Meryem Anayurt , Serpil Sancar 

The incidence of burn-related hypertrophic scar development reaches 70%.^[1] Scars formed after burns can cause significant morbidity, including functional and psychosocial impairments, such as pigmentation, contractures, and deformities that affect burn victims after burn treatment. It causes symptoms such as functional impairment, pain, and severe itching.^[2] Treatment of hypertrophic scars is significant for both functional and psychosocial reasons.

Treatment methods such as range of motion exercises, pressure clothing, steroid injections, and silicone applications are used to treat hypertrophic scars, and the effectiveness of these methods varies depending on the patient.^[3-5] In recent years, promising studies have been published regarding the efficacy of laser application in treating post-burn hypertrophic scars in children.^[3]

Keloids and hypertrophic scars are fibroproliferative disorders of the skin resulting from abnormal healing of burned skin. The epidermis and papillary layer of the dermis are almost normal, except for mild inflammation, and the only abnormality is in the reticular layer of the dermis.^[6] It is due to angiogenesis and abnormal collagen production due to chronic inflammation of the dermis.^[6,7]

Received: May 05, 2024

Accepted: May 22, 2024

Published online: July 03, 2024

Correspondence: Sabriye Dayi, MD.

E-mail: sabriyedayi@yahoo.com

Department of Pediatric Surgery, University of Health Sciences, Bursa City Hospital, Bursa, Türkiye

Citation:

Dayi S, Dede B, İşçimen S, Anayurt M, Sancar S. First results of laser treatment in our pediatric burn patients. Turkish J Ped Surg 2024;38(2):i-vii. doi: 10.62114/JTAPS.2024.42.

Abstract

Objectives: This study aimed to share the first results of the laser application we started using in our center to treat hypertrophic scars formed after burns.

Patients and methods: The retrospective study was conducted with 10 pediatric patients (5 males, 5 females; median age: 3.5 years; range, 30 month to 10 years) treated for post-burn hypertrophic scars between January 2023 and July 2023. Burn patients to whom we applied Nd:YAG (neodymium:yttrium aluminum garnet) laser due to complaints such as contracture, hypertrophic scar, and itching were evaluated. Of all patients who underwent laser application, some received intralesional steroid application during the same session. The patient's age, sex, burn agent, burn percentage, scar areas, number of sessions, post-laser complaints, findings, the patient scar assessment scale (PSAS), and the observer scar assessment scale (OSAS) were evaluated.

Results: The burn agent was two flame burns and eight scald burns. A graft was not applied in four patients, and a graft was used in six patients. The time between the burn dates and laser application ranged between seven months and eight years. One patient underwent four laser sessions, one patient had three laser sessions, and the other patients underwent one session. It was observed in the controls that after laser application, the itching decreased significantly, the hypertrophic scar softened, and its color faded. The PSAS and OSAS scores were found to be statistically significantly reduced ($p < 0.01$).

Conclusion: In the treatment of post-burn hypertrophic scars with Nd:YAG laser treatment, the hypertrophic scar softens, its color fades, itching decreases significantly, and there is a decrease in contracture. Treatment satisfaction of patients and parents had a positive psychological impact on the family. Furthermore, laser therapy can reduce the cost of expensive post-burn care. The increasing use of laser applications also reveals the need for standardization.

Keywords: Burn, child, contracture, Nd:YAG laser, hypertrophic scar.

Long-pulse, 1064-nm Nd:YAG (neodymium:yttrium aluminum garnet) laser is essential in treatment algorithms for keloids and

hypertrophic scars. The Nd:YAG laser is known to have good results in treating deep vascular diseases, such as hypertrophic scars. This laser is used in the treatment of inflammatory scars and vascular lesions. It is also used for hair epilation and skin rejuvenation.^[8] The larger the spot size, power, or fluence, the deeper the laser beam penetrates. Therefore, large spot size and power are used for deep targets, such as hair follicles and blood vessels in the reticular layer of the dermis.^[7] The Nd:YAG laser is used in these pathological scars, characterized by vascular overgrowth, resulting in the accumulation of nerve fibers and collagen in the reticular layer of the dermis. It has been suggested that it acts by suppressing neovascularization.^[8] Long-pulse, 1064-nm Nd:YAG laser therapy can effectively treat keloid and hypertrophic scars by reducing their vascularity. This decrease in vascularity may reduce cytokine or growth factor levels in the tissue. Vascular suppressive treatments are thought to reduce inflammation and scar healing through this mechanism.^[7] The Nd:YAG laser treatment improves scars by reducing abnormal collagen production.^[8] This study aimed to present the early results of Nd:YAG laser treatment, which we started to use in the treatment of post-burn hypertrophic scars at the pediatric burn center of our hospital.

PATIENTS AND METHODS

The retrospective study was conducted with 10 pediatric patients (5 males, 5 females; median age: 3.5 years; range, 30 month to 10 years) treated with Nd:YAG laser for post-burn hypertrophic scars in the pediatric burn center of the Bursa City Hospital, Department of Pediatric Surgery between January 2023 and July 2023. The patients' demographic characteristics (sex, age, and weight), burn agent, burn percentage, graft status, the time between burn occurrence and laser treatment, number of laser sessions, complaints, findings, and the patient scar assessment scale (PSAS) and the observer scar assessment scale (OSAS) and were evaluated.

The PSAS is formed by six items that patients (parents or caregivers of pediatric patients) fill by assessing their scars (pain, pruritus, color, relief, thickness, and pliability); OSAS is formed by six items that observers fill by evaluating their scars (vascularization, pigmentation, thickness, surface roughness, pliability, and surface area).

In our clinic, the laser rejuvenation module of the 1,064 wavelength Nd:YAG laser was applied to all patients. All of our laser applications were performed as an outpatient under anesthesia. In the same session, an intralesional diluted steroid (triamcinolone acetonide) was administered depending on the hypertrophic scar condition. It was added to very dense scar areas after laser application. Places where only laser was applied and areas where steroids were used along with laser were noted. Antibiotic cream was applied to the treated areas and discharged on the same day. The control interval was one and two weeks later. Approximately one to two months later, the patient was called for the second session of laser application.

Statistical analysis

All statistical analyses were performed using IBM SPSS version 25.0 software (IBM Corp., Armonk, NY, USA). Descriptive statistics analysis was used. A p-value <0.05 was considered statistically significant.

RESULTS

The patients' weight ranged between 13 and 30 kg. The burn agent was two flame burns and eight scald burns. There was no need for grafting in four patients, and grafting was applied in six patients. The time between the burn dates and laser application ranged between seven months and eight years (Table 1). In laser application, priority was given to patients with severe hypertrophic scarring and unbearable itching that did not respond to medications and contractures.

The patients' files revealed that they used scar-reducing cream, silicone, and a pressure garment, but the children's compliance was not very good, particularly in those with a large scar surface area on the pressure garment.

The patients with severe complaints and symptoms whom we prioritized for laser treatment are discussed in this paragraph. One patient had laser application four times. One patient had laser application three times. The other patients had one session. Of all patients who underwent laser application, some received intralesional steroid application during the same session. It was observed during control examinations that itching decreased significantly after laser treatment (Table 2). The hypertrophic scar softened, and its color faded in

TABLE 1
Demographic characteristics of patients and other characteristics

| Patients | Age (year) | Sex | Burn agent | Burn surface area | Scar surface area | The time between the burn date and the laser date (month) | Pre-laser PSAS score/ post-laser PSAS score | Pre-laser OSAS score/ post-laser OSAS score |
|----------|------------|--------|------------------|-------------------|-------------------|---|--|--|
| | | | | % | % | n | <i>p</i> | <i>p</i> |
| 1 | 2.5 | Male | Scalding (milk) | 13.50 | 6.00 | 7 | 54/40; <0.001 | 43/31; <0.001 |
| 2 | 2.5 | Male | Scalding (water) | 11.00 | 4.00 | 18 | 28/21; <0.001 | 25/19; <0.001 |
| 3 | 3 | Female | Scalding (water) | 5.50 | 3.00 | 8 | 45/37; <0.001 | 37/31; <0.001 |
| 4 | 4.5 | Female | Scalding (water) | Unknown | 18.00 | 15 | 48/39; <0.001 | 46/40; <0.001 |
| 5 | 10 | Male | Scalding (water) | Unknown | 2.00 | 96 | 18/14; <0.001 | 15/10; <0.001 |
| 6 | 7 | Female | Scalding (water) | 5.50 | 3.50 | 10 | 41/31; <0.001 | 31/24; <0.001 |
| 7 | 3 | Female | Scalding (tea) | 3.50 | 1.50 | 10 | 33/26; <0.001 | 25/20; <0.001 |
| 8 | 4 | Male | Flame | 14.00 | 4.50 | 6 | 23/19; <0.001 | 18/11; <0.001 |
| 9 | 6 | Female | Flame | 12.50 | 4.00 | 8 | 32/27; <0.001 | 19/12; <0.001 |
| 10 | 3 | Male | Flame | 49.00 | 22.00 | 8 | 54/44; <0.001 | 52/46; <0.001 |

PSAS: Patient scar assessment scale; OSAS: Observer scar assessment scale.

heavily scarred areas where the laser was applied with or without steroids (Figures 1-4). A regression in pain symptoms was noted in all of our patients.

Although the families of all laser-applied patients were told not to keep their expectations high during the laser application, it was observed that both the families and the children were happier, and their self-confidence increased after the laser application.

DISCUSSION

Burn is a public health problem that has high mortality and morbidity and negatively affects our lives with its functional, psychological, and social aspects. In the emergency approach, after the struggle for survival and success is achieved, patients move on to the rehabilitation phase for functional disorders and psychological problems that may be temporary or permanent. Some of

TABLE 2
Comparison of pre- and posttreatment scores

| | Mean±SD | Median | 1 | <i>p</i> |
|-----------------------|------------|--------|-------|----------|
| Pre-laser PSAS score | 37.6±12.71 | 37 | 18-54 | <0.001 |
| Post-laser PSAS score | 29.8±10.05 | 29 | 14-44 | |
| Pre-laser OSAS score | 31.1±12.85 | 28 | 15-52 | <0.001 |
| Post-laser OSAS score | 24.4±12.41 | 22 | 10-46 | |

SD: Standard deviation; PSAS: Patient scar assessment scale; OSAS: Observer scar assessment scale.

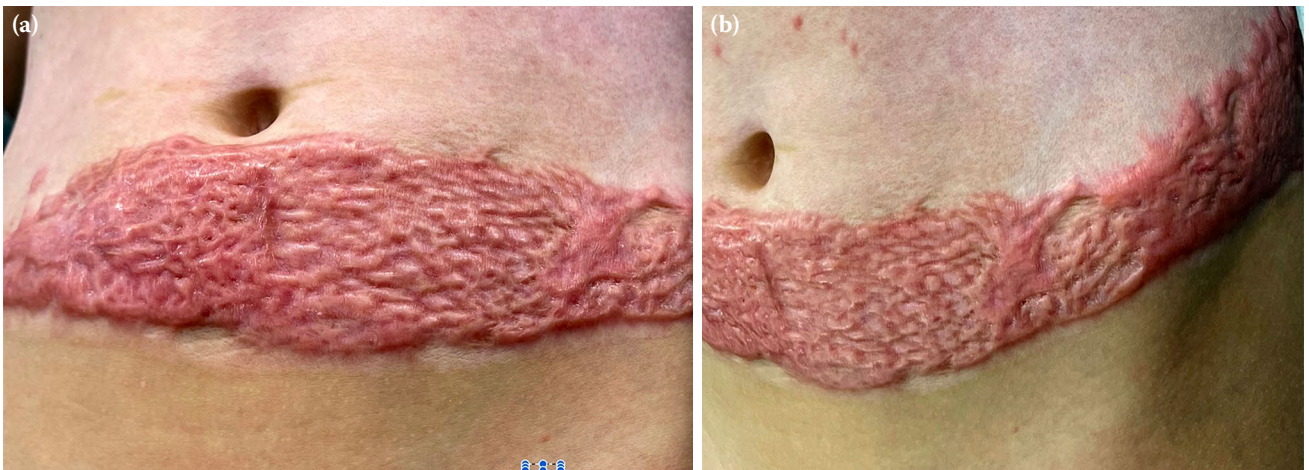


Figure 1. (a) Before laser + steroid application; (b) after laser + steroid application.

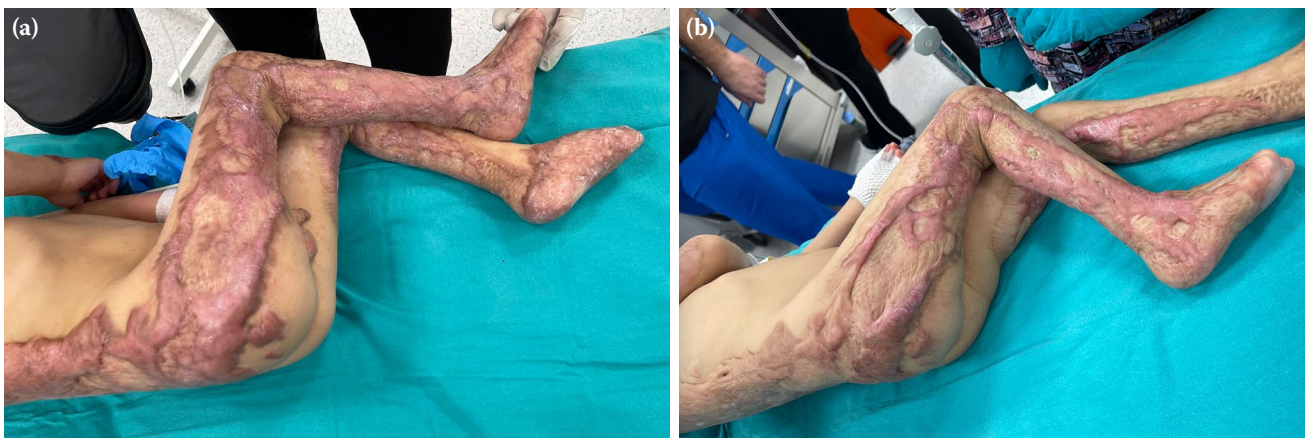

Figure 2. (a) Before laser application; (b) after laser application.

these are performed in the early period before discharge, and some are performed after emergency treatment and the patient is discharged. Early burn wound treatment approaches include dressing, debridement, and graft applications to prevent infection and prevent or minimize scar formation. Despite all efforts in this direction, some patients develop hypertrophic scars.^[3,9,10] Patients not receiving emergency or appropriate burn wound treatment also apply to burn outpatient clinics in the late period. Different treatment methods are used for patients with hypertrophic scars after burns. Conservative treatment includes pressure clothing, steroid applications, and silicone applications.^[4,5]

In one of our patients, a significant discoloration, a decrease in scar height, and a significant decrease in itching were observed in the lower extremities, in whom we did not apply steroids due to an extensive scar area (Figure 2). In addition, similar positive results were obtained in another patient in the scar area in whom the only laser was applied to the facial area (Figure 3). However, comparative prospective studies in large case groups will reveal the effect of laser alone more clearly.

Recently, studies on laser application in adults and children have begun to be published. Ablative fractional laser resurfacing is an emerging treatment for adult skin scar contractures. Recent

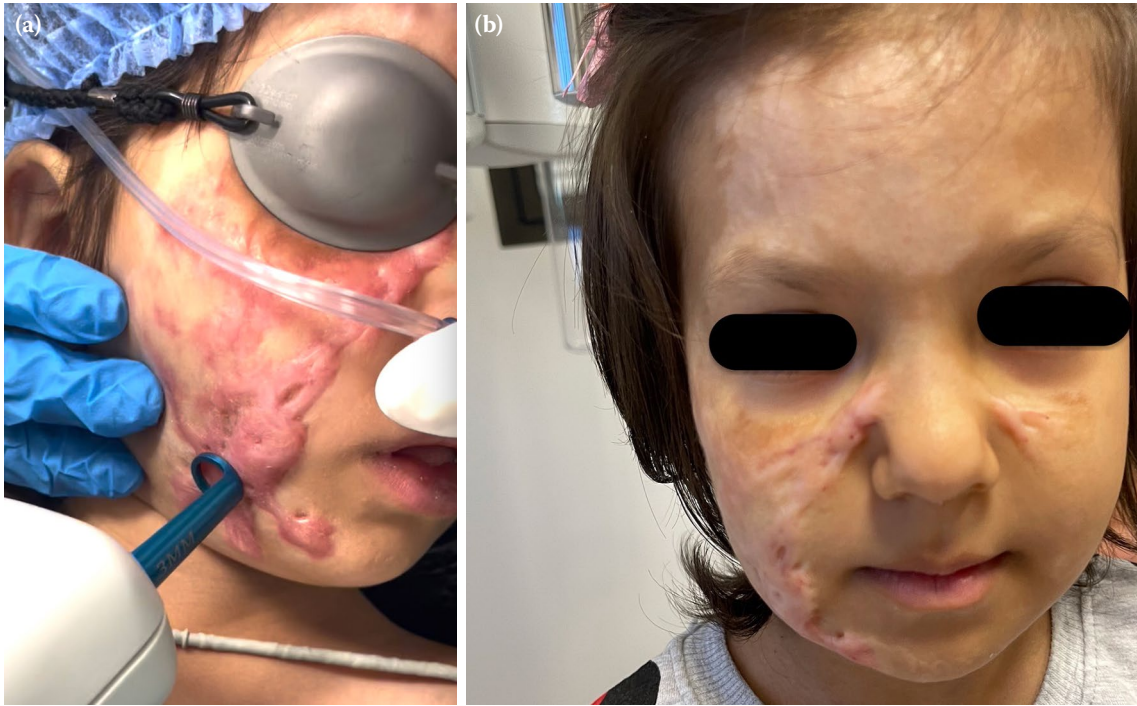

Figure 3. (a) Before laser application; (b) after laser application.

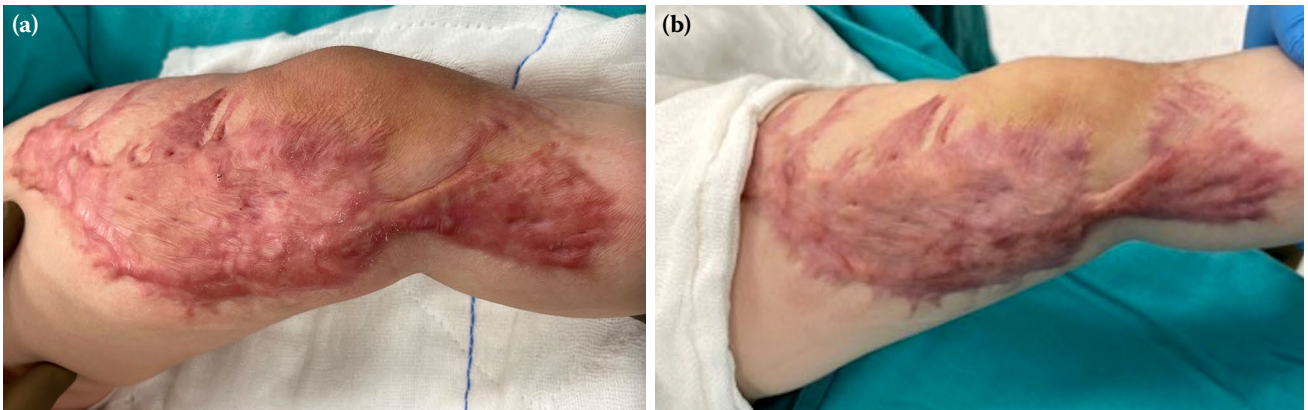


Figure 4. (a) Before laser + steroid application; (b) after laser + steroid application.

reports suggest that ablative fractional laser can lead to consistent improvements in appearance, function, and symptoms such as pain and pruritus in severe traumatic scars.^[11-13] In the application of pulsed dye laser, a reduction in redness has been shown through selective thermolysis in blood vessels.^[9,14] Ablative fractional carbon dioxide laser can reduce the width and thickness of scar tissue

and may contribute to the recovery of the function of the scarred area.^[12,15] One of the lasers used in hypertrophic scars is a nonablative laser, such as the Nd:YAG laser.^[7,8,14,16] Al-Mohamady et al.'s^[14] study showed that using Nd:YAG laser provides good results in treating scars by reducing collagen production. An advantage of the Nd:YAG laser is its ability to penetrate deeper into the skin.^[16] In our study, the ND:YAG laser was used due to the deep

and severe burn scars and the availability of the ND:YAG laser in our institution.

Our patients observed softening of hypertrophic scar tissues and decreased redness after laser application. The regression control in the scar and redness was confirmed with the photographs taken before and after the procedure. The satisfaction of the family and the child with the result can also be considered a psychosocial gain. In the same session, intralesional steroid injection was also administered to areas with intense scar depth. Intralesional steroid injection can help improve hypertrophic scar areas.^[4,17] Areas where steroid injections were made were added to the surgery notes. Improvement in scarring was observed in areas where steroids were administered and in regions without steroid injections. In our study, the improvement in all areas showed the effective results of both laser alone and combined use. Prospective studies, including scar measurements, are needed for a more objective evaluation of scars.

The effects of burn scars include not only the scar's appearance but also the accompanying symptoms. Rashaan et al.^[2] found that up to 47% of patients felt pain associated with burn scars. In addition, they reported that 67% of burn patients still have itching even two years after the burn. In our patient group, the most significant improvement in the early period was the regression in itching symptoms. The decrease in itching may occur after the tension in the scar decreases or in a way whose mechanism we do not know. Additionally, a reduction in pain complaints was observed in our study group.

Pressure clothing and silicone applications used in burn and scar treatment are expensive. Laser treatment is much less costly than other treatments. In this regard, laser treatment can reduce costs compared to expensive treatment options. Another advantage is that the procedure can be done daily. Performing the daily procedure ensures patient and family comfort during treatment. Day treatment is also an advantage in terms of limited bed capacity and use of hospital resources.

Although laser application is a modality that has recently started to be used in burn scars, there has yet to be a standard for patient selection, timing, frequency, and the type of modality that should be used. The increasing use of laser applications also reveals the need for standardization. Therefore,

prospective randomized clinical studies are required.

Since the OSAS and PSAS scores used in scar evaluation have the potential to create different results due to the different people evaluating the patient when the patient comes to laser application it would be more guiding in terms of objectivity to consider this when a prospective study is planned. The effect of the laser may vary depending on the features chosen by the user. The laser that automatically detects the scar thickness and internal structure and applies it will make laser application more effective.

In conclusion, early results of Nd:YAG laser application in burn scar treatment revealed a reduction in itching symptoms, redness, and softening of the scar. The Nd:YAG laser can be considered an effective method for burn scars. However, prospective studies are needed on this subject.

Ethics Committee Approval: The study protocol was approved by the Bursa City Hospital Ethics Committee (date: 05.10.2023, no: 2023–16/11). The study was conducted in accordance with the principles of the Declaration of Helsinki.

Patient Consent for Publication: A written informed consent was obtained from the parents and/or legal guardians of the patients.

Data Sharing Statement: The data that support the findings of this study are available from the corresponding author upon reasonable request.

Author Contributions: Designed the study, contributed to the interpretation of the data, drafted the manuscript, wrote, and edited: S.D.; Collected data and performed analysis and interpretation of the data: B.D.; Collected data and contributed to the interpretation of the data, and drafted the manuscript: S.İ., M.A., S.S. All authors read and approved the final manuscript.

Conflict of Interest: The authors declared no conflicts of interest with respect to the authorship and/or publication of this article.

Funding: The authors received no financial support for the research and/or authorship of this article.

REFERENCES

1. Bombaro KM, Engrav LH, Carrougher GJ, Wiechman SA, Faucher L, Costa BA, et al. What is the prevalence of hypertrophic scarring following burns? *Burns* 2003;29:299-302. doi: 10.1016/s0305-4179(03)00067-6.
2. Rashaan ZM, Kwa KAA, van der Wal MBA, Tuinebreijer WE, van Zuijlen PPM, Breederveld RS. Patterns and predictors of burn scar outcome in the first 12 months after burn: The patient's perspective. *Burns* 2019;45:1283-90. doi: 10.1016/j.burns.2019.03.025.

3. Zuccaro J, Muser I, Singh M, Yu J, Kelly C, Fish J. Laser therapy for pediatric burn scars: Focusing on a combined treatment approach. *J Burn Care Res* 2018;39:457-62. doi: 10.1093/jbcr/irx008.
4. Arno AI, Gauglitz GG, Barret JP, Jeschke MG. Up-to-date approach to manage keloids and hypertrophic scars: A useful guide. *Burns* 2014;40:1255-66. doi: 10.1016/j.burns.2014.02.011.
5. Richard R, Baryza MJ, Carr JA, Dewey WS, Dougherty ME, Forbes-Duchart L, et al. Burn rehabilitation and research: Proceedings of a consensus summit. *J Burn Care Res* 2009;30:543-73. doi: 10.1097/BCR.0b013e3181adcd93.
6. Huang C, Murphy GF, Akaishi S, Ogawa R. Keloids and hypertrophic scars: Update and future directions. *Plast Reconstr Surg Glob Open* 2013;1:e25. doi: 10.1097/GOX.0b013e31829c4597.
7. Ogawa R. Long-Pulsed 1064 nm Nd:YAG Laser Treatment for Keloids and Hypertrophic Scars. In: Téot L, Mustoe TA, Middelkoop E, Gauglitz GG, editors. *Textbook on scar management*. Cham: Springer; 2020. p. 271-8.
8. Koike S, Akaishi S, Nagashima Y, Dohi T, Hyakusoku H, Ogawa R. Nd:YAG laser treatment for keloids and hypertrophic scars: An analysis of 102 cases. *Plast Reconstr Surg Glob Open* 2015;2:e272. doi: 10.1097/GOX.0000000000000231.
8. Blome-Eberwein S, Gogal C, Weiss MJ, Boorse D, Pagella P. Prospective evaluation of fractional CO2 laser treatment of mature burn scars. *J Burn Care Res* 2016;37:379-87. doi: 10.1097/BCR.0000000000000383.
10. Alster TS, Tanzi EL. Hypertrophic scars and keloids: Etiology and management. *Am J Clin Dermatol* 2003;4:235-43. doi: 10.2165/00128071-200304040-00003.
11. Krakowski AC, Goldenberg A, Eichenfield LF, Murray JP, Shumaker PR. Ablative fractional laser resurfacing helps treat restrictive pediatric scar contractures. *Pediatrics* 2014;134:e1700-5. doi: 10.1542/peds.2014-1586.
12. Ozog DM, Liu A, Chaffins ML, Ormsby AH, Fincher EF, Chipps LK, et al. Evaluation of clinical results, histological architecture, and collagen expression following treatment of mature burn scars with a fractional carbon dioxide laser. *JAMA Dermatol* 2013;149:50-7. doi: 10.1001/2013.jamadermatol.668.
13. Hultman CS, Edkins RE, Wu C, Calvert CT, Cairns BA. Prospective, before-after cohort study to assess the efficacy of laser therapy on hypertrophic burn scars. *Ann Plast Surg* 2013;70:521-6. doi: 10.1097/SAP.0b013e31827eac5e.
14. Al-Mohamady Ael-S, Ibrahim SM, Muhammad MM. Pulsed dye laser versus long-pulsed Nd:YAG laser in the treatment of hypertrophic scars and keloid: A comparative randomized split-scar trial. *J Cosmet Laser Ther* 2016;18:208-12. doi: 10.3109/14764172.2015.1114648.
15. Khandelwal A, Yelvington M, Tang X, Brown S. Ablative fractional photothermolysis for the treatment of hypertrophic burn scars in adult and pediatric patients: A single surgeon's experience. *J Burn Care Res* 2014;35:455-63. doi: 10.1097/BCR.0000000000000028.
16. Arora P, Sarkar R, Garg VK, Arya L. Lasers for treatment of melasma and post-inflammatory hyperpigmentation. *J Cutan Aesthet Surg* 2012;5:93-103. doi: 10.4103/0974-2077.99436.
17. Arno AI, Gauglitz GG, Barret JP, Jeschke MG. Up-to-date approach to manage keloids and hypertrophic scars: a useful guide. *Burns* 2014;40:1255-66. doi: 10.1016/j.burns.2014.02.011.