

A rarely seen fast-growing tumor of the breast: Pseudoangiomatous stromal hyperplasia

Sefa Sag¹, Esmâ Karadeniz Güngörmez¹, Feyza Basar²

A limited number of children have breast complaints compared to adults.^[1] However, the frequency of breast complaints in this age group has been increasing in recent years. The most common tumors in children are fibroadenoma, hamartoma, and benign phyllodes tumor.^[2] Pseudoangiomatous stromal hyperplasia (PASH) is very rare, with a few cases reported in the pediatric age group.^[1-3] In this study, we presented a case of a rapidly growing breast tumor diagnosed as PASH.

CASE REPORT

A 13-year-old female patient was admitted to the outpatient clinic with complaints of pain persisting for 10 days and an increase in the size of the left breast. The medical and family history was not remarkable. On physical examination, a painful, solid mass with smooth borders filling almost the entire left breast was noted. Redness, tenderness, and satellite signs on the skin were observed. Axillary examination was unremarkable. The patient had no history of breast surgery or trauma and a family history of breast cancer. In breast ultrasonography, a 9×6 cm, well-defined, hypoechoic,

Abstract

Pseudoangiomatous stromal hyperplasia (PASH) is a benign lesion consisting of proliferated stromal cells of the breast with anastomotic slits reminding vascular spaces. It is very rare in childhood. In our study, we presented a 13-year-old female patient with a rapidly growing breast tumor diagnosed as PASH.

Keywords: Adolescent, breast diseases, hyperplasia, pathology.

slightly heterogeneous, and hypervascular solid mass lesion covering approximately 80% of the left breast parenchyma was detected. The findings led us to consider a differential diagnosis between phyllodes tumor and PASH. Bilateral axillary lymphadenopathy was not observed (BIRADS [Breast Imaging Reporting and Data System] category 4). The noteworthy laboratory test results were as follows: CA 15-3, 19.1 U/m (reference: 0-26.2 U/mL); lactate dehydrogenase, 173 U/L (reference: 120-300 U/L); erythrocyte sedimentation rate, 2 mm/h (reference: 2-20 mm/h); white blood cell count, $5.89 \times 10^3/uL$ (reference: 4.0-12.0 $10^3/uL$); and hemoglobin, 9.4 g/dL (reference: 12-16 g/dL). During the follow-up, the mass grew faster on the first day compared to the previous day. Due to the rapid growth of a large breast mass in an adolescent girl, decision for an emergency operation was made with a presumptive initial diagnosis of phyllodes tumor. A small incision was made around the areola, and a biopsy was taken from the mass for frozen section examination. The histopathology report did not reveal any evidence in favor of malignancy. Subsequently, the mass of approximately 20×15 cm in size was excised together with its capsule (Figure 1). The case was reported as PASH (Figure 2). In the postoperative follow-up of the patient, both breasts were equal in size, and the surgical scar was minimal. The patient was referred

Received: January 04, 2024
Accepted: April 17, 2024
Published online: June 04, 2024
Correspondence: Sefa Sag, MD.
E-mail: drsefa51@gmail.com

¹Department of Pediatric Surgery, University of Health Sciences, Sancaktepe Şehit Prof. Dr. İlhan Varank Training and Research Hospital, İstanbul, Türkiye

²Department of Pathology, University of Health Sciences, Sancaktepe Şehit Prof. Dr. İlhan Varank Training and Research Hospital, İstanbul, Türkiye

Citation:

Sag S, Karadeniz Güngörmez E, Basar F. A rarely seen fast-growing tumor of the breast: Pseudoangiomatous stromal hyperplasia. Turkish J Ped Surg 2024;38(2):65-67. doi: 10.62114/JTAPS.2024.15.

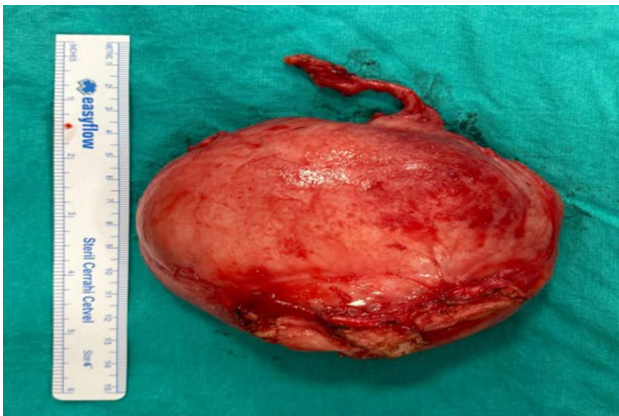

Figure 1. Postoperative image of the mass.

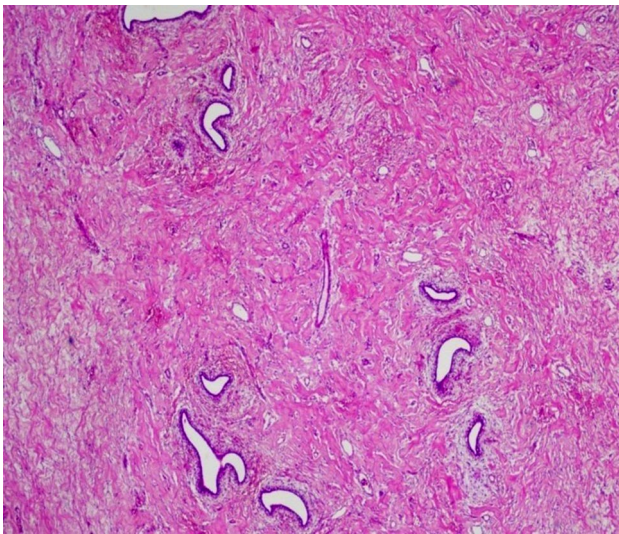


Figure 2. Slightly dilated ducts and surrounding stromal reaction. Hypercellular stroma without vascular proliferation (H&E, $\times 40$).

to pediatric oncology. No issue was detected during the one-year follow-up of the patient. Follow-up is continued intermittently at six-month intervals.

DISCUSSION

Pseudoangiomatous stromal hyperplasia is a benign lesion consisting of proliferated stromal cells of the breast with anastomotic slits reminding vascular spaces.^[3] It often resembles a fibroadenoma but can often be also confused with angiosarcoma or other types of benign vascular proliferations.^[3] Pseudoangiomatous stromal hyperplasia has been

accepted as an important entity in the differential diagnosis of adult breast lesions since it was first defined in 1986.^[4] It is most commonly defined in premenopausal women with a mean age of 37 years.^[5] Although the exact etiopathogenesis is not known, its occurrence in premenopausal and postmenopausal women suggests that hormonal factors play a role.^[6-8]

In PASH, which is clinically well defined in adults, patients may present with the complaint of increased breast size, and it can be detected incidentally during microscopic examination of the biopsy specimen. There are very few pediatric case reports on this subject, and patients usually complain of a rapid increase in breast size and a palpable mass in the breast.^[6,7,9-15] In addition, PASH can be detected microscopically by chance in children or adolescents who have undergone surgery for gynecomastia or macromastia.^[6] Our patient applied with the complaint of a rapid increase in the size of the left breast for the last 10 days. The patient had no additional disease.

In studies reporting pediatric PASH cases, magnetic resonance imaging was generally used in addition to ultrasonography.^[16,17] However, in our patient, since the mass in the breast grew rapidly on the first day, we decided to excise the mass without waiting for magnetic resonance imaging. We believe that ultrasound is also an adequate diagnostic imaging tool.

There is no consensus on the surgical treatment of PASH since it is very rare in the pediatric age group. Although mastectomy is an alternative treatment for extensive PASH involvement of the breast in adult patients, it is reported that excision of the mass only is often sufficiently curative.^[4,5] In childhood, the most common treatment approach is total excision of the mass.^[6,7,9-15] However, Almohawes et al.^[18] performed mass excision together with partial mastectomy in a 12-year-old female patient. Bayramoğlu et al.^[17] published a case of a breast implant application together with partial mastectomy. However, studies published recently have suggested that total excision of the mass in childhood is sufficiently curative.^[2,3] Moreover, studies have reported that recurrence occurs only in nontotal excisions.^[2,3,14,16,19] Although we followed our patients for a limited period of time, we believe that total excision of the mass through a small incision is sufficiently curative in patients with PASH.

In conclusion, we consider surgical treatment to be sufficiently curative without impairing the integrity of the breast in PASH patients.

Patient Consent for Publication: A written informed consent was obtained from the parent of the patient.

Data Sharing Statement: The data that support the findings of this study are available from the corresponding author upon reasonable request.

Author Contributions: Idea/consept, desing, analysis, critical review: S.S.; Data collection: S.S., E.K.G., F.B.; Literature review, writing: E.K.G.

Conflict of Interest: The authors declared no conflicts of interest with respect to the authorship and/or publication of this article.

Funding: The authors received no financial support for the research and/or authorship of this article.

REFERENCES

1. Sekmenli T, Koksall H, Gunduz M, Bostanci H, Ciftci I, Koksall Y. Comparison of the radiologic and clinical findings of adolescents with breast complaints. *J Pediatr Hematol Oncol* 2018;40:295-7. doi: 10.1097/MPH.0000000000001079.
2. Zmora O, Klin B, Iacob C, Meital A, Mendlovic S, Karni T. Characterizing excised breast masses in children and adolescents-Can a more aggressive pathology be predicted? *J Pediatr Surg* 2020;55:2197-200. doi: 10.1016/j.jpedsurg.2020.01.012.
3. Shehata BM, Fishman I, Collings MH, Wang J, Poulik JM, Ricketts RR, et al. Pseudoangiomatous stromal hyperplasia of the breast in pediatric patients: An underrecognized entity. *Pediatr Dev Pathol* 2009;12:450-4. doi: 10.2350/08-09-0528.1.
4. Vuitch MF, Rosen PP, Erlandson RA. Pseudoangiomatous hyperplasia of mammary stroma. *Hum Pathol* 1986;17:185-91. doi: 10.1016/s0046-8177(86)80292-1.
5. Powell CM, Cranor ML, Rosen PP. Pseudoangiomatous stromal hyperplasia (PASH). A mammary stromal tumor with myofibroblastic differentiation. *Am J Surg Pathol* 1995;19:270-7. doi: 10.1097/0000478-199503000-00004.
6. Gow KW, Mayfield JK, Lloyd D, Shehata BM. Pseudoangiomatous stromal hyperplasia of the breast in two adolescent females. *Am Surg* 2004;70:605-8.
7. Singh KA, Lewis MM, Runge RL, Carlson GW. Pseudoangiomatous stromal hyperplasia. A case for bilateral mastectomy in a 12-year-old girl. *Breast J* 2007;13:603-6. doi: 10.1111/j.1524-4741.2007.00499.x.
8. Leon ME, Leon MA, Ahuja J, Garcia FU. Nodular myofibroblastic stromal hyperplasia of the mammary gland as an accurate name for pseudoangiomatous stromal hyperplasia of the mammary gland. *Breast J* 2002;8:290-3. doi: 10.1046/j.1524-4741.2002.08508.x.
9. Lipper S, Willson CF, Copeland KC. Pseudogynecomastia due to neurofibromatosis--a light microscopic and ultrastructural study. *Hum Pathol* 1981;12:755-9. doi: 10.1016/s0046-8177(81)80180-3.
10. Damiani S, Eusebi V. Gynecomastia in type-1 neurofibromatosis with features of pseudoangiomatous stromal hyperplasia with giant cells. Report of two cases. *Virchows Arch* 2001;438:513-6. doi: 10.1007/s004280100399.
11. Zamecnik M, Michal M, Gogora M, Mukensnabl P, Dobias V, Vano M. Gynecomastia with pseudoangiomatous stromal hyperplasia and multinucleated giant cells. Association with neurofibromatosis type 1. *Virchows Arch* 2002;441:85-7. doi: 10.1007/s00428-002-0656-3.
12. Baker M, Chen H, Latchaw L, Memoli V, Ornvold K. Pseudoangiomatous stromal hyperplasia of the breast in a 10-year-old girl. *J Pediatr Surg* 2011;46:e27-31. doi: 10.1016/j.jpedsurg.2011.04.063.
13. Kimura S, Tanimoto A, Shimajiri S, Sasaguri T, Yamada S, Wang KY, et al. Unilateral gynecomastia and pseudoangiomatous stromal hyperplasia in neurofibromatosis: Case report and review of the literature. *Pathol Res Pract* 2012;208:318-22. doi: 10.1016/j.prp.2012.03.003.
14. Testori A, Alloisio M, Errico V, Bottoni E, Voulaz E, Fernandez B, et al. Pseudoangiomatous stromal hyperplasia - a benign and rare tumor of the breast in an adolescent: A case report. *J Med Case Rep* 2017;11:284. doi: 10.1186/s13256-017-1426-9.
15. Jonckheere J, Vanhoeij M, Garkalne I, Antic M, Schiettecatte A, de Mey J. A rare cause of unilateral breast swelling in a male infant caused by fibrous hamartoma of infancy combined with pseudoangiomatous stromal hyperplasia. *Radiol Case Rep* 2019;15:234-6. doi: 10.1016/j.radcr.2019.11.015.
16. Koksall H, Kara B, Eren Karanis MI, Sen S, Koksall Y. Pseudoangiomatous stromal hyperplasia of breast in an adolescent: A case report and review of the literature. *J Pediatr Adolesc Gynecol* 2021;34:209-12. doi: 10.1016/j.jpag.2020.12.005.
17. Bayramoglu Z, Yilmaz R, Caliskan E, Onder S, Akkavak G, Adaletli I. Unilateral rapid enlargement of an adolescent breast: Pseudoangiomatous stromal hyperplasia in a giant juvenile fibroadenoma. *Breast J* 2018;24:648-9. doi: 10.1111/tbj.13030.
18. Almohawes E, Khoumais N, Arafah M. Pseudoangiomatous stromal hyperplasia of the breast: A case report of a 12-year-old girl. *Radiol Case Rep* 2015;10:1-4. doi: 10.1016/j.radcr.2015.06.007.
19. Woo SH, Kang H, Choi WJ, Kim EK. Pseudoangiomatous stromal hyperplasia of the breast in a female adolescent presenting as bilateral gigantomastia. *J Breast Cancer* 2023;26:391-6. doi: 10.4048/jbc.2023.26.e21.